IEOC/an-vision Inc. Equine Ophthalmology Symposium

The Embassy Suites
Saratoga Springs, New York

June 1-3, 2017

International Equine Ophthalmology Consortium
PO Box 1311 Meridian ID 83680 | 208-466-2519 | office@equineophtho.org

IEOC/an-vision Inc. Equine Ophthalmology Symposium

June 1-3, 2017

The Embassy Suites | Saratoga Springs, New York

The goal of this symposium is to share, with a small group of dedicated clinicians and scientists, current clinical and basic research on equine ophthalmology. Abstract and case presentations, along with social events, will facilitate the development of multi-centered collaborative research.

This symposium is sponsored by:

Exhibitors

an-vision Inc.
9067 S. 1300 W., Suite 104
Salt Lake City, UT 84088
Contact: Joyce Wickham
(801) 561-5040
www.an-vision.com

Protective Pet Solutions
1420 E. Roseville Pkwy, #140161
Roseville, CA 95661
Contact: Gayla Burk
(844) 487-7387
www.protectivepetsolutions.com

Stokes Pharmacy
8000 Commerce Parkway, Suite 600
Mount Laure, NJ 08054
Contact: Stacy Milazzo
(856) 975-0908
www.stokespharmacy.com

2017 IEOC/AN-VISION INC. SYMPOSIUM PROGRAM

Time	Room	Event	Presenter	Title/Topic
Thursday, June 1				
6:00pm-8:00pm	Skidmore	Welcome Reception/Registration ***Attendee name badge required/guest ticket required.***		
Friday, June 2				
7:30am	Congress Foyer	Registration desk open		
7:00am-8:30am		Breakfast in Hotel Dining Room (provided with room reservation)		
8:30am-8:45am	Congress	Welcome and Introduction	E. Tolar	
8:45am-9:45am	Congress	State of The Art Lecture	Dr. Chris Sanchez	"Ocular Manifestations of Systemic Disease"
9:45am-10:00am	***State Seal***	***Break with Exhibitors***		
10:00am-11:00am	Congress	State of the Art Lecture	Dr. Chris Sanchez	"Systemic Manifestations of Ocular Disease"
11:00am-12:20pm	**Scientific Abstract Presentations**		**Moderator**	*15 minute presentations, 5 minute Q&A*
11:00am	Congress		T. Barros	CHILEAN WILDFIRE... EYE BURNS IN LOCAL EQUINES
11:20am	Congress		M. Armour	A RETROSPECTIVE REVIEW OF PERIOCULAR AND OCULAR EQUINE MASTOCYTOSIS (MAST CELL TUMOR)
11:40am	Congress		W. Townsend	PREVALENCE OF EQUINE HERPESVIRUS 2 AND 5 WITHIN THE AQUEOUS HUMOR OF NORMAL ADULT HORSES
12:00pm	Congress		E. Crabtree	STANDING ENUCLEATION IN 61 HORSES: CLINICAL DESCRIPTION AND OUTCOMES
12:20pm-1:20pm	***State Seal***	***Lunch with Exhibitors (Attendees only) name badge required.***		
1:20pm-2:40pm	**Scientific Abstract Presentations**		**Moderator**	*15 minute presentations, 5 minute Q&A*
1:20pm	Congress		K. Knickelbein	EQUINE RETROBULBAR DISEASE: DIAGNOSES AND OUTCOMES OF 15 HORSES WITH EXOPHTHALMOS (1988-2015)
1:40pm	Congress		J. Fragola	MICROPHTHALMIA WITH MULTIPLE OCULAR ABNORMALITIES IN 11 HORSES: A NOVEL SYNDROME
2:00pm	Congress		L. Strom	ELECTROPHYSIOLOGICAL FINDINGS IN SIX HORSES WITH VISUAL IMPAIRMENT
2:20pm	Congress		J. Boggs	EVALUATION OF THE EFFICACY OF A LEPTOSPIRA POMONA BACTERIN IN HORSES
2:40pm-3:00pm	***State Seal***	***Break with Exhibitors***		
3:00pm-4:45pm	**Case Reports**		**Moderator**	*10 minute presentations, 5 minute discussion*
3:00pm	Congress		A. O'Reilly	Ocular Manifestation of Amyloidosis

Time	Room	Event	Presenter	Title/Topic
Friday, June 2 Continued				
3:15pm	Congress		A. Metzler	Equine Corneal Epithelial Inclusion Cyst Acute Corneal Decompensation after Initiation of Voriconazole Topical Therapy for Deep Stromal Fungal Abscesses in 2 Horses
3:30pm	Congress		C. Nunnery	Successful Treatment of Penetrating Intraocular Foreign Body
3:45pm	Congress		A. Dwyer	Long Term Outcome of a Corneal Laceration Treated with Medical Therapy
4:00pm	Congress		P. Moore	Calcific Keratopathy Associated with Immune-Mediated Keratopathy
4:15pm	Congress		R. Allbaugh	Orbital Abscessation in a Quarterhorse Gelding
4:30pm	Congress		B. Foote	Successful Use of an Indwelling Retrobulbar Cathether to Treat Bacterial Orbital Cellulitis Secondary to Penetrating Trauma
4:45pm	Conclude			
5:30pm-6:00pm	***Attendees take bus to Wishing Well Restaurant (Ticket is required)***			
6:00pm-8:30pm	***Dinner at Wishing Well Restaurant***			
8:30pm-9:00pm	***Return to Hotel***			

Time	Room	Event	Presenter	Title/Topic
Saturday, June 3				
7:00am-8:30am		Breakfast in Hotel Dining Room (provided with room reservation)		
8:00am	Congress Foyer	Registration Desk Open		
8:30am-8:45am	Congress	Speaker Introduction		
8:45am-9:45am	Congress	State of the Art Lecture	Dr. Lauren Schnabel	"Principles of Stem Cell Therapies: Knowledge Gained and Knowledge Still to Obtain"
9:45am-10:00am	***State Room***	***Break with Exhibitors***		
10:00am-11:00am	Congress	State of the Art Lecture	Dr. Lauren Schnabel	"Ophthalmologic Applications of Stem Cells: Specific Focus on Corneal Wound Healing and Immune-Medicated Keratitis"
11:00am-12:00pm	**Scientific Abstract Presentations**		**Moderator**	*15 minute presentations, 5 minute Q&A*
11:00am	Congress		S. Edwards	EFFECT OF 0.5% PROPARACAINE ON BACTERIAL AND FUNGAL CULTURE RESULTS FROM HORSES WITH ULCERATIVE KERATITIS
11:20am	Congress		E. Ledbetter	*IN VIVO* CONFOCAL MICROSCOPY FINDINGS IN EQUINE EPITHELIAL AND SUBEPITHELIAL NONULCERATIVE KERATOMYCOSIS
11:40am	Congress		B. Fischer	INTRASTROMAL INJECTIONS OF 1% VORICONAZOLE AND REDUCTION IN TOPICAL TREATMENT FREQUENCIES TO TREAT ANTERIOR STROMAL KERATOMYCOSIS IN HORSES

Time	Room	Event	Presenter	Title/Topic
Saturday, June 3 Continued				
12:00pm-1:00pm	***State Room***	***Lunch with Exhibitors (Attendees only) name badge required.***		
1:00pm-2:00pm	**Scientific Abstract Presentations**		**Moderator**	*15 minute presentations, 5 minute Q&A*
1:00pm	Congress		R. McMullen	LOW-DOSE INTRAVITREAL INJECTIONS OF 4MG GENTAMICIN AND SUPERFICIAL LAMELLAR KERATECTOMY COMBINED WITH CONJUNCTIVAL ADVANCEMENT GRAFTS TO CONTROL CHRONIC HETEROCHROMIC IRIDOCYCLITIS AND SECONDARY KERATITIS (HIK): PRELIMINARY RESULTS
1:20pm	Congress		G. Ben-Shlomo	EVALUATION OF INTERLEUKIN-6 EXPRESSION IN AN *EX VIVO* MODEL OF EQUINE CORNEAL WOUND-HEALING
1:40pm	Congress		B. Gilger	COMPARATIVE ANALYSIS OF FUNGAL GENOMES OF ISOLATES FROM EQUINE KERATITIS
2:00pm	Congress		M. Lassaline	EQUINE INTRAOCULAR MELANOCYTIC TUMORS TREATED WITH STANDING DIODE LASER PHOTOCOAGULATION AND CONCURRENT XENOGENEIC TYROSINASE VACCINE: ONE YEAR OUTCOME
2:20pm-2:45pm	***State Seal***	***Break with Exhibitors***		
2:45pm-4:00pm	**Case Reports**		**Moderator**	*10 minute presentations, 5 minute discussion*
2:45pm	Congress		K. Blohm	Modified Medial Canthoplasty in a 20-Year Old Shetland Pony Mare with Lagophthalmos After Chronic Eyelid Laceration
3:00pm	Congress		C. Nunnery	Lateral Canthoplasty to Facilitate Wide Resection of Eyelid Tumors
3:15pm	Congress		R. Allbaugh	Enophthalmos and Restrictive Strabismus in a Connemara Gelding
3:30pm	Congress		K. Knickelbein	Traumatic Extrusion of the Lens to the Episcleral Space
3:45pm	Congress		T. Launois	Triple Ostectomy Orbitectomy in a Horse for Retrieval of a Foreign Body at the Coronoid Process Diagnosed with an MRI
4:00pm	Congress		S. Pryor	Periocular Neomycin Reaction in an Appaloosa
4:15pm-4:45pm	**Congress**	**IEOC Member Business Meeting**		Agenda emailed to members pre-symposium.
4:45pm	**Adjourn**			
5:00pm-6:00pm	**TBD**	**IEOC Board Meeting**		

IEOC/AN-VISION INC. SYMPOSIUM INDEX
LISTED IN ORDER OF PRESENTATION

Saturday, June 3rd

Abstracts

Case Reports



State of the Art Lecturer

Dr. Chris Sanchez

DVM, DACVIM, PhD
University of Florida, College of Veterinary Medicine,
Gainesville, FL 32610-0136

Dr. Sanchez received her DVM degree from the University of Florida in 1995. She then completed an internship at Equine Medical Associates in Edmond, OK and a residency in Large Animal Internal Medicine (1999) and PhD (2003) at the University of Florida. She is currently an associate professor of large animal internal medicine and Medical Director of the Large Animal Hospital at the University of Florida. Dr. Sanchez's clinical interests include general equine internal medicine, neonatology, and gastroenterology. Her research focus has been veterinary gastroenterology, with a special interest in visceral pain and gastric ulceration.

Ocular Manifestations of Systemic Disease and Systemic Manifestations of Ocular Disease in the Horse

L. Chris Sanchez, DVM, PhD, Associate Professor of Large Animal Internal Medicine and
Caryn Plummer, Associate Professor of Ophthalmology
University of Florida College of Veterinary Medicine, Gainesville, FL USA
sanchezl@ufl.edu

Take Home Message

Many systemic inflammatory diseases in horses have ocular signs, and many ophthalmic diseases (or their treatment) can have or result in systemic signs. Thus, it is important to look at the whole horse when considering treatment plans or prognoses. Though the proceedings are organized by specific manifestations, the talk will be entirely case-based in an effort to provide a clinical backdrop to the discussion. A complete list and discussion of every systemic condition that may have ocular manifestations is beyond the scope of this lecture.

Ocular Manifestations of Systemic Disease

Neontatal sepsis/SIRS

Sepsis can occur through different routes, including the placenta in utero, the respiratory tract, the gastrointestinal tract, the umbilical stump, penetrating trauma or secondary to other disorders such as prematurity/dysmaturity, failure of passive transfer, or neonatal encephalopathy. The septic foal may show clinical signs immediately or be healthy at birth and develop signs such as diarrhea, lethargy, fever or hypothermia, decreased suckling or other behaviors within 24-48 hours. Bacteremic foals may seed bacteria to various organs, including the eye. The first sign of septic uveitis is usually a green hue to the iris and anterior chamber as fibrin seeps out of the uveal vasculature. Additional signs of uveitis follow and typically include miosis, globe hypotony (low IOP), aqueous flare, conjunctival and episcleral injection. Occasionally hypopyon and hyphema may develop. Ocular signs may be unilateral or bilateral. Systemic antimicrobial therapy and generalized support are critical to survival. The uveitis must be addressed with symptomatic anti-inflammatory therapy if intraocular scarring is to be avoided. As long as no corneal ulcer is present, topical medical treatment should consist of steroids and atropine. If tolerable, systemic flunixin will benefit the eyes. Occasionally, fibrin will completely fill the anterior chamber and be slow to resorb. If it does not improve rapidly, intracameral tissue plasminogen activator (TPA) may be very helpful to hasten its dissolution.

Rhodococcus equi

Ocular manifestations of *R. equi* include uveitis and occasionally hyphema. These signs may develop as the result of sepsis or a systemic inflammatory response associated with pneumonia. Signs of uveitis typically include epihora, blepharospasm, photophobia, corneal edema, miosis, aqueous flare and significant accumulations of fibrin in the anterior chamber. Severe cases can present with panuveitis, endophthalmitis and vitreal abscess formation. If the uveitis is not controlled adequately, intraocular scarring and cataract formation may result. As such, screening thoracic radiographs are recommended in all foals presenting for surgery associated with congenital cataracts. Concurrent *R. equi* infection greatly impacts the success of cataract removal and the well-being of the patient. Medical treatment for *Rhodococcus*-induced uveitis is symptomatic, with topical anti-inflammatory drugs, atropine and judicious intracameral TPA if needed to resolve fibrin.

Salmonellosis

Salmonellosis is a common infectious enteric disease in horses. Septic horses may have signs ranging from conjunctival and scleral hemorrhages to a severe fibrinous iridocyclitis. *Salmonella* spp. have been recovered from the anterior chambers of affected horses. Fibrin clots typically clear with topical and systemic treatment. The most common signs of ocular involvement are the classic signs of anterior uveitis and hypopyon. Most animals with ocular signs are bacteremic, thus ocular involvement is more common in foals/weanlings. Treatment of salmonellosis-related uveitis should aim to decrease inflammation, prevent synechia formation, and relieve ocular pain. Topical corticosteroids and atropine are used most commonly.

Lyme

Borrelia burgdorferi is a spirochete that may cause panuveitis in horses. Ocular signs are generally nonspecific and panuveitis (anterior and posterior uveitis) may be mild to severe. Hyphema has been reported. Treatment is symptomatic with topical corticosteroids and atropine and systemic flunixin meglumine. Spirochetes have been found inside the eyes of severe cases of panuveitis. When neurologic signs are present in a systemically ill animal, facial nerve paralysis is prominent which can predispose the patient to exposure keratitis.

Tetanus

Tetanus is a highly fatal, infectious disease caused by the toxin of *Clostridium tetani*. The disease causes muscular rigidity, hyperesthesia and convulsions in horses of all ages. The main action of tetanospasmin is to block the release of inhibitory neurotransmitter. Therefore, reflexes normally inhibited by descending inhibitory motor tracts or by inhibitory interneurons (polysynaptic reflexes) are greatly facilitated, resulting in tetanic contractions of muscles after normal sensory stimulation. The most prominent ocular sign in horses with tetanus is prolapse of the nictitans, which may make a flickering motion when the horse is stimulated ("flick of the haw"). Other signs are facial muscle spasms, anxious expressions, flared nostrils, and erect ears. The eye may be enophthalmic because of retractor bulbi muscle contraction.

Leptospirosis

Both acute iridocyclitis and equine recurrent uveitis (ERU) may be initiated by Leptospiral organisms. The exact mechanism by which Leptospiral organisms induce and sustain recurrent uveitis is not well understood, however, it is believed that some degree of molecular mimicry may trick the immune system into mounting and auto-immune attack against the eye. Bacterial antigens and antibodies have been found in the equine eye. Experimental infections with leptospiral organisms has been associated with the development of clinical uveitis even up to one year after initial infection. However, not every horse infected with lepto will develop uveitis or recurrent uveitis. Peripapillary depigmented chorioretinal lesions may occur with acute or subacute infections of the retina and choroid. A persistent vitritis similar to ERU may be caused by Leptospiral infection and is responsive to vitrectomy therapy.

Strangles

Equine strangles is a highly contagious purulent lymphadenitis of the upper respiratory tract caused by the gram-positive *Streptococcus equi subsp. equi (S. equi).* Dissemination may be hematogenous or via lymphatic vessel and results in abscesses in lymph nodes and other organs of the thorax and abdomen. The lack of efficacy of neutrophils in phagocytosing and killing S. equi is due to a combination of the hyaluronic acid capsule, antiphagocytic M-protein (SeM), and a leukocidal toxin released by the organism. Although the disease primarily involves the upper airways and associated lymph nodes, spread to other to other locations

may occur. A mucopurulent conjunctivitis develops with naturally occurring streptococcal infections. Severe bilateral iridocyclitis may occur. Multifocal chorioretinitis, optic neuritis, retinal hemorrhage, and retinal detachment have also been observed in foals. Intracranial abscesses can cause loss of pupillary reflexes, unilateral or bilateral blindness, nystagmus, head tremors, and/or head tilt. Guttural pouch infection by *Streptococcus equi* may lead to facial nerve paresis/paralysis or Horner's syndrome. Corneal ulcers infected with *S. Equi* can be particularly challenging to treat and may progress rapidly.

Equine Herpervirus

The equine herpesviruses are contagious, prevalent and potentially performance-limiting. These viruses can be immunosuppressive. EHV-1 is a common cause of upper respiratory tract infection, abortion and, less commonly, neurologic disease (Equine Herpes Myeloencephalopathy/EHM). EHV -1 and -4 have been isolated from horses with bilateral conjunctivitis and respiratory signs and are often associated with non-specific hyperemia of the conjunctiva and sclera. EHM-afflicted horses may have associated blindness, strabismus, ptosis, iridocyclitis, KCS, facial nerve paralysis, retinal hemorrhage, or optic neuritis. EHV-2 has been associated with a variety of ocular signs, including serous discharge, conjunctival hyperemia, chemosis, punctate to linear corneal opacities, corneal edema and vascularization. Antiviral therapies have been employed with variable or questionable efficacy. Supportive care is usually most important.

Equine protozoal myeloencephalitis (EPM)

Equine protozoal myeloencephalitis (EPM) is a common neurological disease of horses in the Americas; causative agents include *Sarcocystis neurona* (most commonly) and *Neospora hughesii*. Neurological signs associated with EPM vary widely, depending upon the location of infection within the CNS. Asymmetric hind limb weakness, ataxia, and muscle atrophy are reported most commonly. If the brain and/or brainstem are affected, ophthalmic signs may result. Corneal anesthesia can result from trigeminal neuropathy. If EPM affects the brainstem, cranial nerves VII and VIII bay be involved, resulting in facial nerve paralysis (ptosis, absence of menace and palpebral responses) and vestibular disease (nystagmus, strabismus), respectively. If the parasympathetic nucleus of cranial nerve VII is affected, neurogenic keraticonjunctivits sicca (KCS) will result. This condition is very difficult to treat and can predispose the cornea to ulcerations and infectious keratitis. Involvement of cranial nerves III, IV and VI will cause strabismus. Oculomotor (CN III) may also result in pupillary dilation as well as ventrolateral strabismus. If ophthalmic signs are present with EPM, they are usually accompanied by other cranial nerve lesions. EPM affecting the cervical spinal cord can cause Horner’s syndrome (miosis, ptosis, enophthalmos, elevation of the third eyelid and ipsilateral facial and neck sweating).

Pituitary pars intermedia dysfunction (PPID)

Because the pituitary in horses is below the tuber cinereum medially, and the optic tracts laterally, adenomas usually do not compromise the visual system directly. A distended third ventricle will push against the optic chiasm. They may, however, interfere with the blood supply to the optic pathways and thus indirectly produce blindness. Common manifestations of PPID include delayed or failed shedding, PU/PD, muscle wasting, laminitis, chronic infections and delayed wound healing. These patients are at risk for immunosuppression and impaired collagen production. Ocular wounds, such as corneal ulcers can be very slow to heal, more susceptible to infection and therefore, more difficult to treat. Diagnosis of corneal ulcer in a horse with PPID should be accompanied by a high level of vigilance.

Temporohyoid osteoarthropathy

Temporohyoid osteoarthropathy (THO) is a neurologic condition in adult horses characterized by acute onset of CN VII and CN VIII deficits resulting in facial paralysis and/or vestibular signs. This condition occurs secondary to bony proliferation of the temporohyoid joint and stylohyoid bone that leads to fusion of the TH joint. Fusion of this joint can predispose the animal to fracture of the base of the skull, the shaft of the stylohyoid bone or the petrous temporal bone. This, in turn, leads to damage of the inner and middle ear and the previously noted cranial nerves. Prognosis is guarded and the facial paralysis or paresis may be permanent. Exposure keratitis and corneal ulceration are common and slow to heal without a normal eyelid function.

Systemic Manifestations of Ocular Disease

Large Colon and Cecal Impactions

Large colon impactions are a frequent cause of large intestinal non-strangulating obstruction in the horse. Impaction can occur from a variety of factors, most commonly decreased water intake, decreased overall activity (such as stall confinement due to illness or injury), or a variety of other factors. Cecal impactions occur less commonly, but reported risk factors include surgery for non-gastrointestinal reasons. Horses treated for ophthalmic disease often have multiple risk factors for large colon and or cecal dysfunction, including stall confinement, dietary alterations, and potentially decreased gastrointestinal motility associated with sedation and/or anesthesia, topical administration of atropine, and/or ocular pain. Careful monitoring includes measurement of daily water intake and fecal output and careful monitoring for signs of colic. Medical therapy is typically successful and any decrease in water intake or fecal output should warrant careful scrutiny and/or intervention with oral electrolytes, decrease in hay provided and, potentially enteral fluids. Such intervention should be accompanied by a decrease in frequency of atropine administration. Tropicamide may be employed topically; however, it is not nearly as effective at addressing intraocular inflammation or producing mydriasis.

Right Dorsal Colitis

Ulceration and/or inflammation of the right dorsal colon is the most common ulcerative disorder associated with protein-losing enteropathy in the horse. This condition is most often associated with systemic non-steroidal drug administration; importantly, this can occur as an idiosyncratic reaction, thus does not necessarily indicate NSAID abuse. Clinical signs include dependent edema, colic, weight loss and diarrhea. Clinocpathologic changes often precede clinical signs and include hypoproteinemia secondary to hypoalbuminemia and, infrequently, anemia. Since ophthalmology patients frequently require long-term, high-dose systemic NSAID administration to control intraocular inflammation, they are at particular risk for the development of RDC. It is recommended that any animal on an NSAID for extended periods of time have blood protein concentrations checked regularly. At UF, we created an “NSAID panel” which includes total protein, albumin and creatinine concentrations. Recommended interval to check is at least every 14 days while horses are receiving continuous NSAIDs.

Conclusions

Ocular manifestations of systemic disease occur commonly. An index of suspicion and thorough ophthalmic examinations in systemically ill patients is necessary to provide the best global care to the patient and to prevent ocular pain and potential vision loss. Similarly, the entire horse should be managed when dealing with serious ophthalmic conditions. Prevention

or early treatment of gastrointestinal complications can provide a better prognosis and more efficient, economical treatment.

References

1) Leiva M, Peña T, Armengou L, Cesarini C, Monreal L. Uveal inflammation in septic newborn foals. J Vet Intern Med. 2010 Mar-Apr;24(2):391-7.
2) Reuss SM, Chaffin MK, Cohen ND. Extrapulmonary disorders associated with Rhodococcus equi infection in foals: 150 cases (1987-2007). J Am Vet Med Assoc. 2009 Oct 1;235(7):855-63.
3) Gerhards H, Wollanke B. [Antibody titers against Borrelia in horses in serum and in eyes and occurrence of equine recurrent uveitis]. Berl Munch Tierarztl Wochenschr. 1996 Aug;109(8):273-8.
4) Walker AM, Sellon DC, Cornelisse CJ, Hines MT, Ragle CA, Cohen N, Schott HC. Temporohyoid osteoarthropathy in 33 horses (1993-2000). J Vet Intern Med. 2002 Nov-Dec;16(6):697-703.
5) Davis JL. Ocular manifestations of systemic disease. In: Gilger BC (ed) Equine Ophthalmology 2nd ed. Philadelphia: Elsevier Saunders 2011:443-469.
6) Cullen CL, Webb AA. Ocular manifestations of systemic disease. Part 3: The horse. In Gelatt KN (ed): Veterinary Opthalmology. Ames, IO: Wiley Blackwell. 2013: 2037-2070.

FRIDAY SESSION
ABSTRACTS & CASE REPORTS

CHILEAN WILDFIRE... EYE BURNS IN LOCAL EQUINES (TM Barros,[1] and BC Gilger,[2])
Improvet Chile Ltda. Unidad de Medicina y Cirugia Equina, Hospital Clinico Veterinario UNAB, Universidad Andres Bello, Santiago, Chile,[1]; North Carolina State University, Raleigh, North Carolina, USA,[2]

Purpose. To describe ocular examinations and lesions found in horses after wildfire burns including treatment at a referral field emergency hospital or referral facility. **Methods.** Severe wild fires in January 2017 devastated central and southern Chile in agricultural areas where a large number of livestock, including horses, were affected. Ocular examinations of burned horses were performed between 4 days and 6 weeks after initial injury. **Results.** More than 500.000 ha (1,235,527 acres) were burned, 11 people died, and hundreds of wild and farm animals, including horses, were burned and many died. The immense magnitude of the wildfires made it very difficult to quickly treat the injured horses and therapy was limited because many owners were poor and had lost everything. It was also difficult to transport affected equines to the field emergency hospital. Many affected horses were not broken or ever handled, so treatment and examination was challenging. Breeds affected were Chilean Criollos, Arabs mix, and draft mix breeds, of all ages and sexes. Most common ocular lesions found included: 100% horses had palpebral skin burn, 44% upper eyelids and 89% lower eyelids; 100% had burned conjunctiva, 22% unilateral, 88% bilateral; incomplete blink or palpebral closure, 11% unilateral, 33% bilateral; 20% had blepharitis; 33% corneal burn (wrinkled cornea); 33% corneal edema; 22% uveitis; 44% blepharospasm; 44% photophobia; 33% epiphora; 22% decreased menace reflex; 44% decreased STT; 44% positive fluorescein; 11% corneal perforation with anterior chamber collapsed; 11% enucleation; 33% eyelid cicatricial retraction; 33% unilateral, 56% bilateral. **Conclusions.** Devastating injuries in the equine eye and periocular tissue occurred after wildfire burns. Delay in examination and treatment affected the treatment and prognosis. There was an association between the worse skin burn with worse ophthalmic thermal burns. When third degree burns involving more than 40-60% of the body and including burned eyes, none of the equine survive. **None**

A RETROSPECTIVE REVIEW OF PERIOCULAR AND OCULAR EQUINE MASTOCYTOSIS (MAST CELL TUMOR) (MD Armour,[1] L Teixera,[2] and K Bordeleau,[3]) Eye Care for Animals, Leesburg VA,[1], COPLOW University of Wisconsin-Madison School of Veterinary Medicine,[2], Private Practice Wellington FL,[3].

Purpose. To describe the cases of periocular and ocular equine mastocytosis. **Methods.** A retrospective analysis of submissions to the Comparative Ocular Pathology Laboratory of Wisconsin database was performed. Veterinary ophthalmologists and (when appropriate) owners were contacted to acquire patient follow up information regarding the case. Patient data collection included signalment, laterality, eye color, location of the mass, surgical margins, adjunctive therapy, recurrence, metastasis and length of follow up. **Results.** Records from 7 horses were identified between 2001 and 2016, including two Warmbloods, one Appaloosa, one Irish draft, one Quarter horse, one Irish sport horse, and one Thoroughbred/Warmblood cross. Patients age ranged from 3 to 21 years. Four right globes and three left globes were included in the study. All patients' eye color reported was brown. Cutaneous mastocytosis was documented in four cases, palpebral conjunctival mastocytosis in three cases. The mastocytosis was incompletely excised in all cases documented except one with clean but narrow margins. **Conclusions.** Periocular and ocular equine mastocytosis is a rare process identified in our veterinary patients. **None.**

PREVALENCE OF EQUINE HERPESVIRUS 2 AND 5 WITHIN THE AQUEOUS HUMOR OF NORMAL ADULT HORSES (WM Townsend[1] and N Pusterla[2]) College of Veterinary Medicine, Purdue University;[1] College of Veterinary Medicine, University of California Davis.[2]

Purpose. To determine the prevalence of EHV-2 and 5 within aqueous humor of normal equine eyes. The study hypothesis was horses will not have PCR detectable EHV-2 or 5 within the aqueous humor despite their EHV status in whole blood, nasal, or conjunctival samples. **Methods.** A prospective, masked study. Horses with respiratory or ocular disease were excluded. Complete ocular examinations were performed. After sedation, aqueous humor was collected from each eye. Single culture swabs were collected from each conjunctival fornix and a pooled swab from both nares. Whole blood was collected in EDTA. Samples were stored at -80^{0}C until PCR analysis at UC Davis. The real-time quantitative PCR for EHV-2 and 5 was performed using the laboratory's standard protocol. **Results.** Samples were collected from 38 eyes of 20 horses with 19 right eyes and 20 left eyes. One eye had previously been enucleated due to known trauma. There were 15 mares and 5 geldings. The median age was 12.5 years (range 3-26 years). No horses had EHV-2 or 5 detected in the aqueous humor. Nine nasal swabs, one blood sample, and 12 conjunctival samples had EHV-2 or 5 DNA detected using PCR. No horses were positive for both EHV-2 and 5 at the same site. **Conclusions.** DNA from EHV-2 and 5 was not detectable within the aqueous humor of clinically normal equine eyes, even if the horses had detectable EHV-2 or 5 DNA within the conjunctival fornices, blood, or nares. **None.**

STANDING ENUCLEATION IN 61 HORSES: CLINICAL DESCRIPTION AND OUTCOMES

(EE Crabtree 1, EL Kilgallon 2, RB Edwards III 1, M Lassaline 3) 1 Fairfield Equine Associates, 2 Miller & Associates, 3 Department of Surgical & Radiological Sciences, University of California, Davis, CA.

Purpose. To examine the safety and outcome of standing enucleation performed in horses in a stable or hospital setting. **Method**. Retrospective medical record review including horses enucleated under standing sedation between 2008 and 2017. Relevant clinical history, ophthalmic examination findings, intra-operative and post-operative complications, and outcomes were recorded. **Results**. Sixty-one horses met inclusion criteria, including 18 mares, 41 geldings and 2 stallions with a median age of 20 years (range 3 to 34 years). Fifty-four enucleations were performed in a hospital setting and seven in the field. Horses were sedated with detomidine, romifidine, or a combination of detomidine and butorphanol, and maintained on a continuous rate infusion or given individual boluses of sedation. Regional anesthesia was provided by anesthesia of the supraorbital nerve, ring block at the margins of the eyelid, and a four-point retrobulbar block. The operated site was bandaged following surgery. Clinical conditions requiring enucleation included uveitis (9), glaucoma (9), trauma (4), deep or melting corneal ulceration (4), recurrent or non-healing corneal ulcer (6) stromal abscess (3), iris prolapse (12), squamous cell carcinoma (5), phthisical eye (5), anterior lens luxation (2), facial nerve paralysis (1) and exophthalmos (1). Median post-operative hospitalization was 2 days (range 0-15). Post-operative complications included orbital infection (5), cecal impaction (1), residual Habronema granuloma (1), purulent bloody discharge (1) and incision dehiscence (1). **Conclusions**. Standing enucleation can be successfully and safely performed in the field or hospital setting with minimal complications, and avoids risks associated with general anesthesia and recovery, which may be particularly beneficial for older horses.

EQUINE RETROBULBAR DISEASE: DIAGNOSES AND OUTCOMES OF 15 HORSES WITH EXOPHTHALMOS (1988-2015). **(**KE Knickelbein,[1] ME Lassaline,[1]) University of California, Davis School of Veterinary Medicine[1]

Purpose. To characterize the clinical findings, diagnostics, therapies, diagnoses, and outcomes of horses with exophthalmos. **Methods**. Medical records at the UC Davis Veterinary Medical Teaching Hospital from 1988-2015 were reviewed for horses with exophthalmos for which a definitive diagnosis was reached. Data obtained included breed, age, sex, diagnostic procedures, therapeutic interventions, histopathologic diagnosis, and outcome. Follow-up information was obtained via telephone or email questionnaire. **Results**. Fifteen horses were included. Mean age of evaluation was 14.1 years (range 6-27 years). Common diagnostics included skull radiography (9), orbital ultrasound (9), and computed tomography (5). Diagnoses included neuroendocrine tumor (3), paranasal sinus cyst (2), Aspergillosis (2), lymphosarcoma (1), spindle cell sarcoma (1), hemangiosarcoma (1), squamous cell carcinoma (1), undifferentiated carcinoma (1), glandular hamartoma (1), myopathy (1), and foreign body (1). Four horses underwent exenteration. One diagnosed with a neuroendocrine tumor showed no evidence of recurrence 18 months post-operatively. One diagnosed with extraocular myopathy showed no further signs at euthanasia 11 years post-operatively. The horse diagnosed with a hamartoma underwent globe-sparing surgical excision and remains alive without recurrence 7 years post-operatively. Two horses were euthanized immediately following CT. Six were euthanized due to progression of disease. One horse was euthanized following a peri-anesthetic complication. Follow-up was unavailable for 3 horses. **Conclusions**. Neoplastic processes comprised 53.3% of cases (8/15). The mean presentation age for neoplasia was similar to that of other etiologies (13.6 and 14.7 years, respectively). Aspergillosis and glandular hamartoma are described as novel etiologies of equine exophthalmos. **None.**

MICROPHTHALMIA WITH MULTIPLE OCULAR ABNORMALITIES IN 11 HORSES: A NOVEL SYNDROME (JA Fragola,[1] LBC Teixeira[1]) Comparative Ocular Pathology Laboratory of Wisconsin, University of Wisconsin School of Veterinary Medicine[1]

Purpose. To report clinicopathological features of a previously unrecognized ocular syndrome in horses characterized by bilateral microphthalmia with severe anterior segment dysgenesis, cartilaginous and glandular choristomatous ocular differentiation, aphakia, and retinal dysplasia. **Methods.** 22 globes from 11 neonatal equines diagnosed with congenital blindness secondary to microphthalmia were identified in the archives of the Comparative Ocular Pathology Laboratory of Wisconsin (COPLOW). Patient signalment, clinical history, and gross and histopathological lesions were reviewed. **Results.** All affected animals were euthanized for congenital blindness shortly after birth. 6/11 were female, 2/11 were male, and the sex of 3/11 was unknown. Affected breeds included Thoroughbred (3/11), Standardbred (1/11), Paint (1/11), Rocky Mountain Spotted Horse (1/11), Quarter Horse (1/11), Arabian cross (1/11) and unknown (3/11). The malformation was bilateral in all cases. The corneal stroma blended with or was replaced by skin, conjunctiva, or scleral-like tissue often containing sebaceous glands or hair follicles. The anterior uveal tract, anterior chamber, and posterior chamber were poorly formed and replaced by choristomatous tissue consisting of cartilage in 21/22 eyes, gland in 18/22 eyes, and connective tissue in 22/22 eyes. All eyes were aphakic, exhibited retinal dysplasia, and 19/22 globes exhibited retinal detachment. **Conclusions.** This investigation describes a novel ocular syndrome in horses characterized by bilateral microphthalmia and aphakia with multiple ocular abnormalities. Given the predominance of anterior segment lesions, a defect during the embryological development of the lens placode is suspected. A specific genetic mutation and the role of toxic and/or infectious agents is yet to be determined. **None.**

ELECTROPHYSIOLOGICAL FINDINGS IN SIX HORSES WITH VISUAL IMPAIRMENT

(L Ström[1], ME Källberg[1] & B Ekesten[1]), [1] Department of Clinical Sciences, Swedish University of Agricultural Sciences, PO Box 7054, SE-750 07 Uppsala, Sweden.

Purpose. To describe electrodiagnostic findings in horses with visual impairment. **Methods.** Physical and eye examinations, including an obstacle course, were performed in six horses admitted to the Swedish University Animal Hospital. Light-adapted FVEPs and FERGs were recorded (RETIport, An-Vision GmbH, Germany) under sedation. **Results.** Uni- or bilateral visual impairment was confirmed in all horses. Case 1 showed no menace responses or dazzle reflexes OU. FERG b-wave peak times were prolonged. FVEPs were undetectable. CT-scan and subsequent autopsy showed a paranasal meningioma, pressing on the optic chiasm. Cases 2 and 3 presented with unilateral exophthalmia. Menace responses and dazzle reflexes were abnormal in affected eyes. FERGs were normal and FVEPs undetectable. Contralateral eyes were normal. Diagnostic imaging and subsequent autopsy showed extra-adrenal paragangliomas compressing the affected optic nerve pre-chiasmatically. Case 4 showed progressive visual impairment during treatment for systemic infection and panuveitis OU. Menace responses and dazzle reflexes were affected. FERG times-to-peaks were prolonged. Late components of the FVEP waveform were abnormal. Systemic inflammatory disease with bilateral panuveitis and meningitis was diagnosed at autopsy. Case 5 presented with a congenital, unilateral, complete cataract. Menace response was absent in the affected eye, dazzle reflex was normal. FERGs were normal OU. The FVEP driven from the affected eye had an immature waveform. Case 6 was diagnosed with unilateral cataract, glaucomatous retinopathy and optic nerve cupping. FERG b-wave amplitudes were reduced. FVEPs were undetectable. **Conclusions.** Different conditions causing visual impairment affect the FERG and FVEP differently. Combining these tests helps localizing the lesion.

EVALUATION OF THE EFFICACY OF A LEPTOSPIRA POMONA BACTERIN IN HORSES

(JJ Boggs, [1] PA Barrett, [2] VL King, [2] ML Keith, [2] and CP Cook [2]) Zoetis, Equine Technical Services, Parsippany, NJ;[1] Zoetis, Veterinary Medicine Research & Development, Kalamazoo, Michigan.[2]

Purpose. The objective of the study was to evaluate the safety and efficacy of Zoetis LEPTO EQ INNOVATOR®* by challenge in horses to support the label claim as an aid in prevention of infections due to *Leptospira pomona*. **Method.** Thirty, 6-month-old female horses, seronegative (MAT antibody titers <8) to *L. interrogans* serovar *pomona, L. bratislava, L. icterohaemorrhagiae, and L. hardjo* were randomly assigned to one of two study groups. Fifteen horses were vaccinated with Zoetis LEPTO EQ INNOVATOR® and 15 horses received sterile saline. The horses received 2 intramuscular vaccinations 3 weeks apart and were monitored following each vaccination for any adverse reactions. Starting 21 days following the second vaccination (Day 42), horses were challenged with *Leptospira interrogans serovar pomona*. Horses were monitored for clinical signs of disease daily starting 2 days prior to challenge (Day 40), through Day 56 and on Days 63 and 70. Clinical signs of leptospirosis were monitored including but not limited to: elevated temperature, depression, changes in appetite or water consumption, icterus (jaundice), ocular discharge, dehydration, oliguria and conjunctivitis. Blood and urine samples were cultured and the culture samples monitored microscopically for the presence or absence of leptospires following challenge. Samples of the kidney and liver were collected at necropsy and also cultured to detect the presence of leptospires. **Results.** The *L. pomona* challenge resulted in fevers and re-isolation of Leptospira from horses. Based on the results of a previous challenge model study, clinical signs were unremarkable. All 15 control horses tested positive by isolation from at least one sample. In contrast, none of vaccinated horses tested positive from any sample. The prevented fraction estimate for Leptospira isolation was 100% (95% CI: 78%, 100%). Ten of the 15 (67%) control horses developed fevers ≥103.0°F, while only three (20%) of the vaccinated horses developed fevers greater ≥103.0°F. **Conclusions.** This study demonstrated the safety and efficacy of Zoetis LEPTO EQ INNOVATOR, a monovalent *Leptospira Pomona* Bacterin, in support of the claim, “For vaccination of healthy horses, 6 months of age or older, for the prevention of leptospirosis caused by *Leptospira interogans serovar pomona*”. Funded by Zoetis. **E**. *Zoetis, 10 Sylvan Way, Parsippany, NJ 07054

Ocular Manifestation of Amyloidosis

Author and Address:
Dr Anu O'Reilly
Melbourne Eye Vet 9-11 Miles Street, Mulgrave, 3170, Melbourne, Australia
Email: anutony@anutony.com.au

Topic Area: Conjunctiva/Systemic disease

Case Summary:
A 17-year-old Paint gelding presented to Melbourne Eye Vet at the South East Equine Hospital for bilateral conjunctivitis due to suspected self-trauma.

Ophthalmic examination revealed haemorrhagic conjunctivitis in both eyes with the remaining ocular exam being normal. On physical examination proliferative oral lesions and enlarged regional lymph nodes were noted. An equine surgical and medicine specialist were consulted and conjunctival, oral and lymph node biopsies, haematology, biochemistry and abdominal ultrasonography were performed. The histological diagnosis revealed amyloidosis of the conjunctiva, gum and lymph node.

The horse was treated with topical and systemic steroid.

Key Words
Amyloidosis, Systemic diseases

Discussion Points:

- Does bilateral ocular disease warrant a complete physical examination?
- What are the treatment options for this patient?

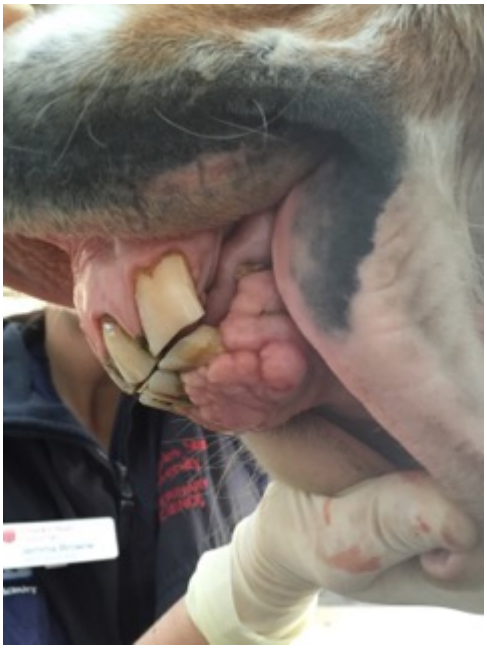

Oral Amyloidosis

Conjunctival Amyloidosis

Acute Corneal Decompensation After Initiation of Voriconazole Topical Therapy For Deep Stromal Fungal Abscesses in Two Horses

Author and Address:
Anne Metzler, DVM, MS, DACVO
Professor-Clinical
The Ohio State University College of Veterinary Medicine
Columbus, OH 43210
Metzler.134@osu.edu

Topic Area:
Cornea

Case Summary:
The clinical progression after initiation of treatment in two cases of deep stromal fungal abscesses will be discussed. Case 1 was a 12-year-old Morgan mare and Case 2 was a 4-year-old Quarter horse gelding. Both cases were receiving antifungal therapy for 1 week and 1 day, respectively, at the time of presentation (Itraconazole + DMSO in Case 1 and silver sulfadiazine in Case 2). Within 12 and 36 hours, respectively, of instituting voriconazole 1% topically at a frequency of q 4 hours in Case 1 and q 12 hours in Case 2, focal severe corneal bulging +/- malacia were observed. The corneal swelling stabilized and resolved in both cases after instituting doxycycline 10 mg/kg PO q 12 hours and serum q 4 hours and temporarily reducing the frequency of voriconazole in Case 1 to q 8 hours. Aggressive medical management was continued and healing via vascularization of the abscess progressed as expected. The author is interested in hearing the experiences of others that have encountered this clinical presentation.

Key Words:
Fungal keratitits, voriconazole, doxycycline, bullous keratopathy, corneal malacia

Discussion Points:
At what frequency should antifungal therapy be initiated?
What is the pathophysiology of the acute severe corneal swelling?
What is the best therapeutic approach when the cornea decompensates after initiation of antifungal therapy?
Does corneal decompensation occur after intra-corneal injection of voriconazole?

Photos (see next page):



Figure 1. Case 1: Initial presentation of deep stromal abscess prior to initiation of voriconazole 1% therapy.

Figure 2. Case 1: Severe focal corneal swelling +/- malacia 12 hours after initiation of voriconazole 1% q 4 hours.

Figure 3. Case 2: Severe corneal swelling/bullous keratopathy 48 hours after initiation of voriconazole 1% q 12 hours.

Successful Treatment of Penetrating Intraocular Foreign Body

Author and Address:
Nunnery, C; Allendorf, S; Cutler, T
Equine Veterinary Vision, Alexandria, VA 22315; Palm Beach Equine Clinic, Wellington, FL 33414; Equine Ophthalmology, Wellington, FL 33414

Topic Area:
Intraocular

Case Summary:
A 10-year-old, warmblood gelding was presented for acute ocular trauma with a history of falling on a broken halter. On examination, the patient had a retained metallic foreign body that pierced through the cornea at the 3-4 o'clock corneal limbus and exited at the 10 o'clock cornea approximately 4mm from the limbus. The anterior chamber was filled with hyphema and fibrin enveloped the metal. The patient received extraction of the foreign body and corneal laceration repair. The anterior chamber was lavaged with LRS containing 1:1000 epinephrine and 1500 units of heparin. Hylartin-V was used to maintain anterior chamber and tamponade iridal bleeding. The corneal lacerations were closed using 7-0 vicryl in a simple interrupted pattern. The patient was treated with intravenous potassium penicillin and gentamycin followed by oral doxycycline. Topical therapy included voriconazole, ofloxacin, serum, atropine and flunixin. The corneal lacerations healed with severe corneal edema being the only temporary complication. The hyphema cleared showing a depigmented and macerated lateral pupil margin. On day 7 a wispy anterior capsular cataract was observed and systemic dexamethasone was started. Topical diclofenac was started on day 21 after complete neovascularization of the lacerations. The patient was visual and comfortable 6 weeks post-op with an unchanged anterior capsular cataract.

Key Words:
Corneal Laceration, Penetrating Foreign Body, Ocular Trauma, Post-Traumatic Cataract

Discussion Points:
Use of conjunctival grafts over corneal laceration repair?
Post traumatic cataract formation? Timing?
Use of systemic steroids with corneal trauma?

Figure 1. Initial presentation retained metallic penetrating foreign body.

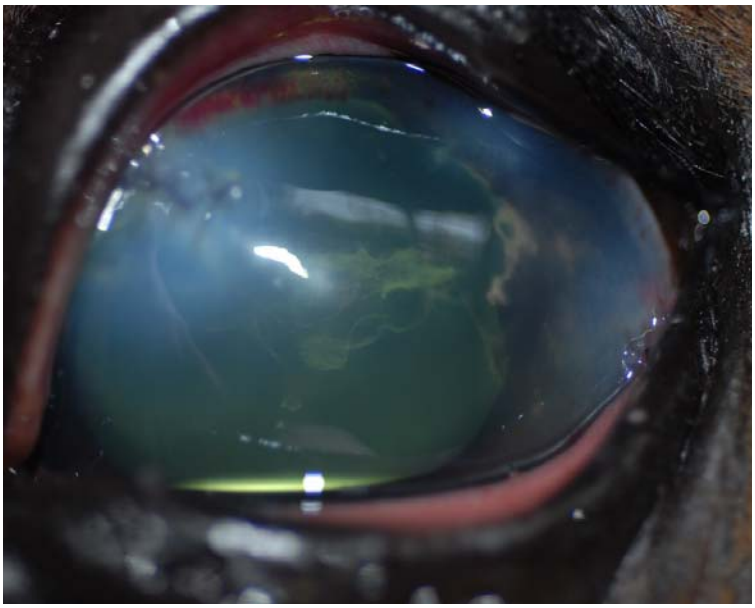

Figure 2. Anterior capsular cataract, depigmented lateral pupil edge and healing corneal lacerations (Day 12).

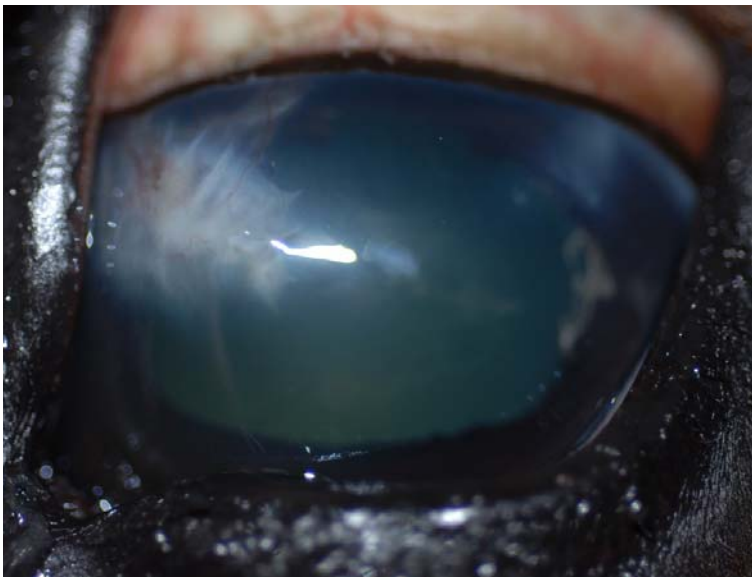

Figure 3. Corneal fibrosis, regressing neovascularization and mild epithelial pigmentation. (Day 42)

Long Term Outcome of a Corneal Laceration Treated With Medical Therapy

Authors and Addresses:
Dwyer A*, Brooks D£, Aquavella J‡, Fischer W‡, Teixeira L§ and Boynton J‡.
* Genesee Valley Equine Clinic, Scottsville, NY 14546 (*presenting author*)
£ University of Florida School of Veterinary Medicine, Department of Ophthalmology, Gainesville, FL 32611
‡ Flaum Eye Institute, Rochester, NY 14642
§ Comparative Ophthalmology Pathology Laboratory of Wisconsin, Madison, WI 53706

Topic Area: Cornea

Case Summary:
An 11 year old Thoroughbred gelding sustained a severe corneal laceration OS. The laceration involved 75% of the horizontal axial diameter and was over 50% stromal depth. The wound was lavaged on the day of occurrence and treated with mydriatic, serum and antimicrobial therapy through an SPL tube for several weeks. Sequential photographs recorded progressive epithelialization and restoration of stromal integrity during the acute healing phase and at subsequent examinations. The horse was euthanized for unrelated reasons at 20 years of age. Both globes were harvested for immediate corneal spectral domain OCT and confocal microscopy. Histopathology was performed on both globes using H&E and Alcian Blue PAS stains. The OCT imaging demonstrated a compact bright signal in the midstromal region of the corneal scar meridians in the affected eye. Histopathology showed superficial stromal loss with moderately hyperplastic epithelium in the scar meridian. Decreased keratinocyte numbers were suggestive of fibrosis of the mature corneal scar. There was moderate increase in Alcian blue and PAS positivity in the same region of the stroma that registered a bright signal on OCT suggesting increased collagen. Confocal microscopy images were similar in the affected and normal eyes in the region of interest.

Key Words: Cornea, OCT, Corneal fibrosis

Discussion Points:

1. Medical vs. surgical therapy of corneal lacerations
2. Wound healing when more than 50% of the corneal stroma is lacerated
3. Challenges of OCT and confocal imaging of the postmortem equine cornea

The images for the submission on the following pages show photographs of the acute, subacute and healed laceration, one OCT image of the scar meridian and histopathology images comparing the scarred cornea with a similar region in the normal fellow eye.

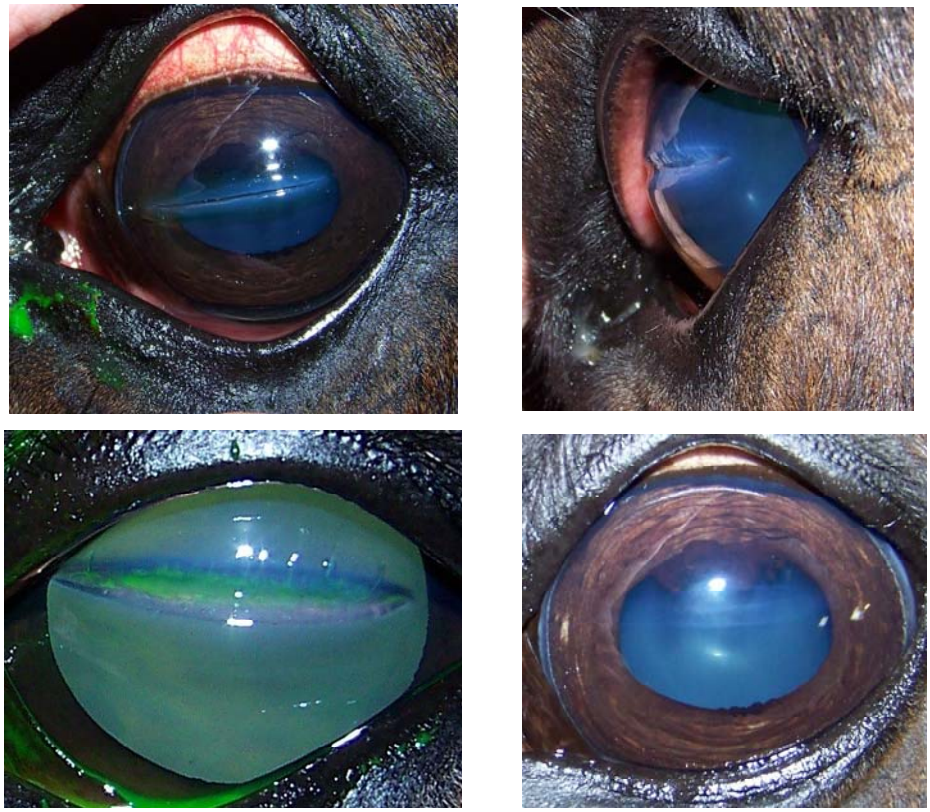

Corneal laceration in a nine year old TB: Acute laceration OS, stromal defect seen at oblique view, early epithelialization, and scar 9 years later

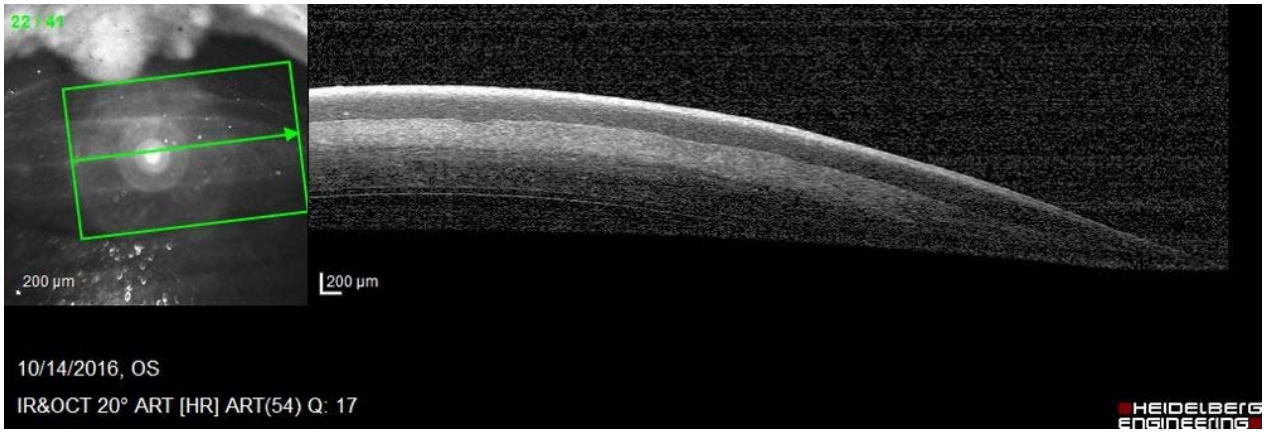

Post mortem OCT image of OS corneal central scar meridian demonstrating compact signal in middle stroma

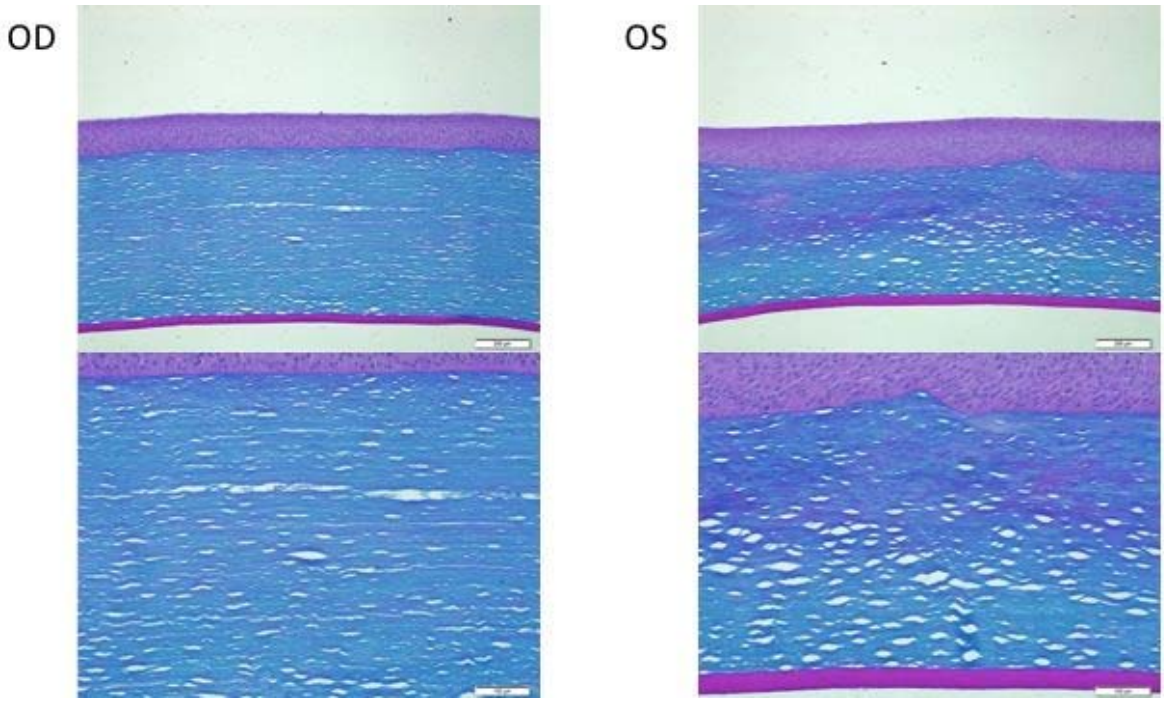

Alcian Blue and PAS stained section of normal OD cornea (left) and central meridian of OS corneal scar (right), showing hyperplastic epithelium, mild stromal thinning and increased positivity in central stroma in the scarred area.

Calcific Keratopathy Associated With Immune-Mediated Keratopathy

Authors and Addresses:
Moore PA, Rodriguez R, Beyer A, McMullen Jr RJ
Department of Clinical Sciences, College of Veterinary Medicine,
Auburn University, Auburn AL, 36849

Topic Area:
Cornea

Case Summary:
A 10 year-old Haflinger, gelding was presented for evaluation of historical ERU and active corneal ulceration. The ERU had intermittently responded to Neo/poly/Dex. 0.1%. Abnormal ophthalmic findings were limited to OS. Examination OS, revealed a white, ground glass appearing, subepithelial infiltrate that encompassed 70% of the cornea. Moderate, superficial corneal neovascularization and an axial, stromal ulceration were present. There was no evidence of ERU. Cytology revealed epithelial cells and mineral consistent with calcium. Culture results revealed a coagulase negative *Staphylococcus* spp. The diagnosis of IMMK with a secondary calcific keratopathy and corneal ulceration was made. Treatment consisted of topical atropine 1%, ofloxacin 0.3%, miconazole 1%, cefazolin 3.3% (q 6hrs) and cyclosporine 1% (q8 hrs), and oral flunixin meglumine. The subepithelial infiltrate and ulceration responded rapidly to treatment. On day 14, the antimicrobials were tapered, and topical EDTA 1% (q6 hrs) and CSA 2% (q8hrs) were initiated. Two month post initial examination, subconjunctival cyclosporine implantation was performed and the topical cyclosporine tapered (q 12 hr). Initial response to the implants was favorable with resolution of the infiltrate and ulceration, leaving an area of corneal fibrosis and mild neovascularization. Two and one-half- months post cyclosporine implants active areas of IMMK were noted.

Key Words:
Equine immune-mediated keratitis, calcific keratopathy, subconjunctival cyclosporine implants

Discussion Points:
Is calcific keratopathy a frequent presentation of IMMK?
Is EDTA a beneficial treatment with calcific keratopathy associated with IMMK?
How long to continue topical cyclosporine post CSA implants and frequency?
Next step: topical NSAID, topical dexamethasone or photodynamic therapy.
Why does IMMK wax and wane with treatment?

Orbital Abscessation in a Quarterhorse Gelding

Authors and Addresses:
Rachel Allbaugh, DVM, MS, DACVO, Travis Strong, DVM, MS (Resident), Rita Wehrman, DVM (Resident), and Gil Ben-Shlomo, DVM, PhD, DACVO, DECVO
Iowa State University Department of Veterinary Clinical Sciences, Ames, IA 50011

Topic Area:
Orbit

Case Summary:
An 24-year-old Quarterhorse gelding presented for non-painful swelling around the left eye of 5 days duration. Ophthalmic examination revealed a blind left eye with severe exophthalmos and resistance to retropulsion. There was severe blepharospasm, severe blepharoedema, and moderate left third eyelid elevation. A central superficial corneal ulcer was present with mild reflex uveitis; however, the left pupil was fixed and mydriatic. Aside from a grade 5/6 heart murmur, physical exam was normal. Ocular ultrasound was performed and was inconclusive. Further work-up was declined. Exenteration was performed 5 days later under general anesthesia due to worsening periocular status. During surgery, an abscess was encountered in the ventrolateral retrobulbar space containing copious purulent, putrid material. Affected tissues were removed, and the orbit was extensively lavaged with diluted povidone iodine in saline. Samples collected showed neutrophils with intralesional bacteria, as well as myriads of extracellular mixed bacteria. The patient was started on systemic oral antibiotics (rifampin 5% solution and SMZ-TMP) while awaiting culture results. No aerobic organisms grew; however, anaerobic *Peptostreptococcus* and *Fusobacterium* species were both isolated so metronidazole 15 mg/kg PO BID was prescribed. Orbital swelling remained pronounced after surgery despite oral NSAID use then started to decline after metronidazole was initiated.

Key Words:
Orbital abscess, exophthalmos, *Peptostreptococus* and *Fusobacterium*

Discussion Points:
1. Others' experiences with equine orbital abscesses?
2. Thoughts on source of infection?

Figure 1. Image of the 24-year-old Quarterhorse gelding prior to exenteration with left periocular swelling, exposure keratitis, and third eyelid protrusion.

Figure 2. Left orbital swelling persisting 5 days post exenteration.

Successful Use of an Indwelling Retrobulbar Catheter to Treat Bacterial Orbital Cellulitis Secondary to Penetrating Trauma

Authors and Address:
Foote, B; Nunnery, C
University of Pennsylvania, Kennett Square, PA 19348

Topic Area:
Orbit

Case Summary:
A 15-year-old warmblood cross gelding was presented to the New Bolton Center Ophthalmology Service for trauma to the left orbit. Clinical abnormalities included mild pyrexia and the left eye exhibited purulent discharge from a lateral canthal laceration, severe pain to palpation of the orbit, exophthalmia, elevated nictitans, marked chemosis, superficial corneal ulcer, fibrin in the anterior chamber and miosis. Diagnostic work up including radiographs, ultrasound, aerobic culture, and exploration of the laceration under standing sedation concluded the wound tracked along the temporal aspect of the globe into the retrobulbar space with surrounding cellulitis and a non-displaced fracture of the dorsal orbital rim. Two species of Streptococcus were identified. Therapy included broad-spectrum antibiotics, a proton pump inhibitor, systemic steroidal and non-steroidal anti-inflammatories, topical ophthalmic antibiotic ointments and a mydriatic agent. In addition, a 12 G Mila catheter was placed through the wound track into the retrobulbar space to facilitate drainage, controlled closure of the wound, and delivery of a local antibiotic. Catheter was in place for a total of 9 days until mucopurulent discharge ceased to drain. Treatment was successful in preserving vision with an excellent cosmetic outcome.

Key Words: orbital cellulitis, trauma, retrobulbar catheter, local antibiotics

Discussion Points:
Safety of local antibiotics in retrobulbar space?
Treatment options for orbital cellulitis?
Other uses for retrobulbar catheters?

Photos and Descriptions (see following pages):

Image 1: Left eye on day of presentation. Note the lateral canthal laceration, severe periorbital swelling, chemosis, ulcerated conjunctiva, and ocular discharge.

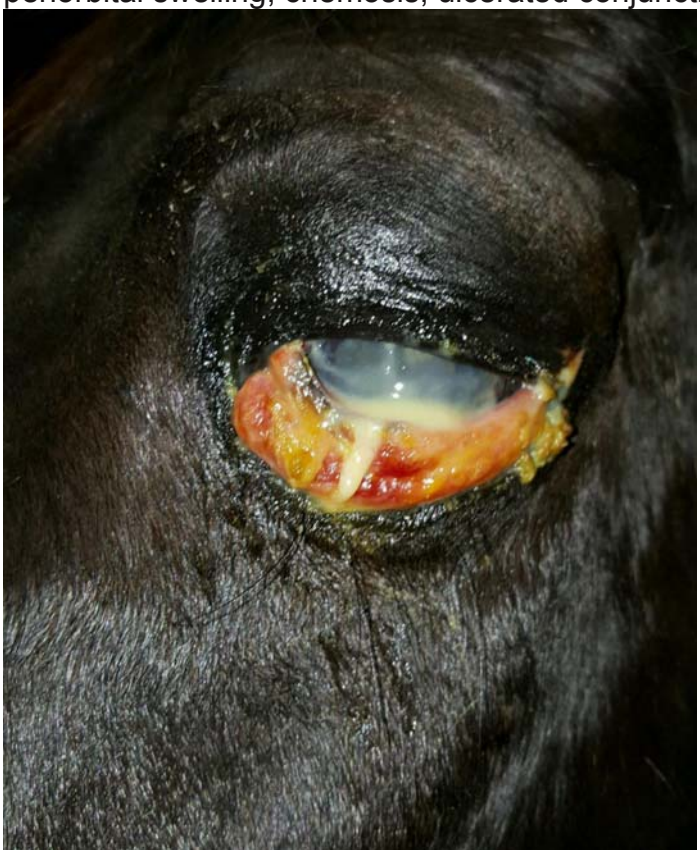

Image 2: Ultrasound image the following day of left orbit and globe. Note the penetrating wound tract to the retrobulbar region and the surrounding cellulitis.

Image 3: Left eye one week post placement of the indwelling retrobulbar catheter. Note the 12 G Mila catheter placed in the wound tract at the lateral canthus sutured in place with 2-0 Ethilon, healthy pink granulation tissue surrounding catheter, no remaining discharge from the wound, and decreased periorbital edema.

State of the Art Lecturer

Dr. Lauren Schnabel

DVM, PhD, DACVS
North Carolina State University,
College of Veterinary Medicine,
Raleigh, NC 27607

Dr. Schnabel grew up in Long Island, New York, where she enjoyed spending time around both sport horses and racehorses. After receiving her bachelor degree from Duke University, she headed back to New York to attend Cornell University for her veterinary degree. She then went on to complete an internship at Rood and Riddle Equine Hospital in Kentucky before returning to Cornell as a postdoctoral fellow in the Orthopedic Laboratories of Dr. Lisa Fortier and Dr. Alan Nixon where she performed research on tendon and ligament repair. Dr. Schnabel completed her surgical residency at Cornell from 2006-2009 and became a Diplomate of the ACVS in 2010. She then completed her Ph.D. with Dr. Fortier on the immunologic properties of stem cells while also working as an emergency surgeon at Cornell.

Dr. Schnabel began her position at NC State in 2013 working in both the equine hospital and her research laboratory. She specializes in the use of regenerative therapies for the treatment of musculoskeletal injuries in horses and has published and given lectures both nationally and internationally on platelet rich plasma, bone marrow aspirate concentrate, and stem cells. In particular, her laboratory is focused on understanding the immunologic and immunomodulatory properties of mesenchymal stem cells. Such knowledge is critical for potential allogeneic “off the shelf” stem cell therapy which would allow us to treat patients at the time of diagnosis rather than having to wait several weeks to months to culture stem cells from that patient.

At NC State, Dr. Schnabel runs the Clinical Mesenchymal Stem Cell Culture Service and is developing the Sports Medicine and Rehabilitation Service at with Dr. Rich Redding and colleagues. Dr. Schnabel became a Diplomate of the ACVSMR in 2015.

Principles of Stem Cell Therapies: Knowledge Gained and Knowledge Still to Obtain

Lauren V. Schnabel, DVM, PhD, DACVS (LA), DACVSMR (Equine)
Assistant Professor of Equine Orthopedic Surgery
Department of Clinical Sciences
North Carolina State University College of Veterinary Medicine, Raleigh, NC 27607, USA

There are many unanswered questions surrounding the therapeutic use of stem cells in horses. In particular, no precise recommendations can be made regarding the selection of a specific regime for a given injury or disease. Additional research studies and prospective clinical trials are needed to determine the appropriate timing of the treatment, dosage of the treatment, and the outcomes the veterinarian should expect following the treatment. In addition, regulatory bodies that would ensure that appropriate standards of care are followed when using stem cell therapies are still in their infancy in veterinary medicine with the first Guidance for Industry (GFI) #218 on "Cell-based Products for Animal Use" (www.fda.gov) released in 2015. The purpose of this talk is to review the types of stem cells available for veterinary use, the current FDA guidelines for stem cell use, and what we have learned through the use of stem cells for the treatment of musculoskeletal injuries over the past decade. An outline is provided below and copies of the power point will be available upon request after the conference.

Types of stem cells

- Adult vs. non-adult
- Multipotent vs. pluripotent
- Cultured expanded vs. non-expanded/point-of-care
- Autologous vs. allogeneic

FDA guidelines

- Type I vs. Type II animal stem cell products
- Homologous vs. non-homologous use
- Investigational New Animal Drug (INAD) for clinical trials, universities
- New Animal Drug Application (NADA) for commercial entities
- What does this mean for the future?

Knowledge gained and lessons learned

- Current uses of stem cells in Equine Sports Medicine and evidence to support their use
- Mechanisms of action
- Delivery methods and vehicles
- Unanswered questions and future directions

Selected References:

Schnabel LV, Fortier LA, McIlwraith CW, Nobert KM. Therapeutic use of stem cells in horses: which type, how, and when?. Vet J. 2013 Sep;197(3):570-7.

Berglund AK, Schnabel LV. Allogeneic major histocompatibility complex-mismatched equine bone marrow-derived mesenchymal stem cells are targeted for death by cytotoxic anti-major histocompatibility complex antibodies. Equine Vet J. 2016 Nov 10; ePub ahead of print.

Pezzanite LM, Fortier LA, Antczak DF, Cassano JM, Brosnahan MM, Miller D, Schnabel LV. Equine allogeneic bone marrow-derived mesenchymal stromal cells elicit antibody responses in vivo. Stem Cell Res Ther. 2015 Apr 12;6:54.

Cassano JM, Schnabel LV, Betacourt AM, Antczak DF, Fortier LA. Mesenchymal stem cell therapy: Clinical progress and opportunities for advancement. Current pathobiology reports. 2015 March; 3:1-7.

Ophthalmologic Applications of Stem Cells: Specific Focus on Corneal Wound Healing and Immune-Mediated Keratitis

Lauren V. Schnabel, DVM, PhD, DACVS (LA), DACVSMR (Equine)
Assistant Professor of Equine Orthopedic Surgery
Co-authors: Amanda B. Sherman, DVM, ACVO Resident,
Brian C. Gilger, DVM, MS, DACVO, ABT and
Alix K. Berglund, DVM, PhD Candidate (Schnabel Lab)
Department of Clinical Sciences
North Carolina State University College of Veterinary Medicine, Raleigh, NC 27607, USA

This talk will build upon Dr. Schnabel's first talk on the "Principles of Stem Cell Therapies: Knowledge Gained and Knowledge Still to Obtain" to apply what we have learned about the mechanisms of action of stem cells, and particularly bone marrow-derived stem cells (BM-MSCs), to the treatment of ocular injuries and pathology. Specifically, the talk will present and discuss the findings of an in-vitro study performed by the authors at NCSU examining the effects of BM-MSCs and BM-MSC supernatant on equine corneal wound healing as well as provide an update on the cases enrolled in our clinical trial on the use of BM-MSCs for the treatment of immune-mediated keratitis (IMMK). An outline is provided below and copies of the power point will be available upon request after the conference.

Ophthalmologic applications of stem cells

- Reasoning
- Evidence from other species and case reports

NCSU in-vitro corneal wound healing study

- Need for alternative therapies
- Methods
- Results and discussion
- Next steps and future directions

NCSU IMMK clinical trial

- Need for alternative therapies
- Update on enrolled cases (previous presented by Dr. Gilger)
- Next steps and future directions

Selected References:

Sherman AB, Gilger BC, Berglund AK, Schnabel LV. Effect of bone marrow-derived mesenchymal stem cells and stem cell supernatant on equine corneal wound healing in vitro. In Revision, Stem Cell Res Ther. 2017.

Marfe G, Massaro-Giordano M, Ranalli M, Cozzoli E, Di Stefano C, Malafoglia V, et al. Blood derived stem cells: An ameliorative therapy in veterinary ophthalmology. J Cell Physiol. 2012;227:1250–1256.

Pate DO, Clode AB, Olivry TM, Cullen JM, Salmon JH, Gilger BC. Immunohistochemical and immunopathologic characterization of superficial stromal immune mediated keratitis in horses. Am J Vet Res 2012;83(7):1069-1073.

Matthews A, Gilger BC. Equine immune mediated keratopathies. Equine Vet Journal 2010;37:62-68.

Matthews A, Gilger BC. Equine immune mediated keratopathies. Vet Ophthalmol:2009:12(S1):10-16.

Gilger BC, Michau TM, Salmon J. Immune-mediated keratitis in horses: 19 cases (1998–2004). Vet Ophthalmology 2005; 8(4):233-239.

SATURDAY SESSION

ABSTRACTS & CASE REPORTS

EFFECT OF 0.5% PROPARACAINE ON BACTERIAL AND FUNGAL CULTURE RESULTS FROM HORSES WITH ULCERATIVE KERATITIS (SG Edwards,1 D Maggs,1 B Byrne,2 PH Kass,3 M Lassaline.1) Department of Surgical and Radiological Sciences;1 Department of Pathology, Microbiology & Immunology;2 Department of Population Health & Reproduction, School of Veterinary Medicine;3 School of Veterinary Medicine, University of California, Davis, CA.

Although topically applied anesthetics likely increase patient comfort during corneal sample collection, their effect on culture results is unknown. **Purpose.** To investigate effects of topically applied proparacaine on bacterial and fungal culture results from horses with ulcerative keratitis. **Methods.** Corneal samples for culture and cytology were collected from twenty horses with ulcerative keratitis. Culture samples were collected prior to and following application of 0.5% proparacaine or saline. Cytology samples were then collected following application of 0.5% tetracaine. Differences in frequency of cultivatable bacteria before and after test agent application were assessed using Fisher's exact test. **Results.** No significant difference was detected in number of horses from which bacteria were cultured before and after application of proparacaine (6/12 and 4/12, respectively; $P = 0.68$) or saline (3/8 for both; $P = 1.00$). Small numbers prevented analysis of number of horses from which fungi were cultured before and after application of proparacaine (2/12 and 1/12, respectively) or saline (1/8 for both). Considering results from both culture samples for each horse collectively, bacteria were cultured from 10/20 horses, but detected cytologically in just 3 of these; fungi were cultured from 3/20 horses and detected cytologically in 2 of these. Fungi were detected cytologically in 2 additional horses from which fungi were not cultured. **Conclusions.** Proparacaine did not statistically alter bacterial or fungal culture results in this population; however clinical significance warrants investigation. Corneal culture and cytology provide complementary data and should both be done to maximize organism detection in horses with ulcerative keratitis. Funded by the Center for Equine Health V4S5357, School of Veterinary Medicine, University of California, Davis. **None.**

IN VIVO CONFOCAL MICROSCOPY FINDINGS IN EQUINE EPITHELIAL AND SUBEPITHELIAL NONULCERATIVE KERATOMYCOSIS (EC Ledbetter,[1] Irby NL,[1] Teixeira LB[2]) Department of Clinical Sciences, College of Veterinary Medicine, Cornell University, Ithaca NY;[1] Department Pathobiological Sciences, School of Veterinary Medicine, University of Wisconsin-Madison, Madison, WI.[2]

Purpose. To described the *in vivo* confocal microscopy features of horses with epithelial and subepithelial nonulcerative keratomycosis. **Methods.** Four horses with a clinical diagnosis of epithelial or subepithelial keratomycosis were examined on one or more occasions by *in vivo* laser scanning confocal microscopy of the cornea. Results of confocal microscopic examinations were correlated with clinical, cytological, histopathological, and microbiological findings. **Results.** All horses had an irregular corneal epithelial surface during slit-lamp biomicroscopy examination. Epithelial or subepithelial corneal opacities were present in multifocal or diffuse patterns. Rose bengal corneal staining was focally or diffusely positive in all cases. Fungal hyphae were detected in cytological or histopathological corneal samples. *Aspergillus*, *Fusarium*, and *Penicillium* spp. were cultured from samples. In horses with epithelial clinical disease, hyphae were diffusely distributed over the axial cornea. Extracellular hyphae were seen in all layers of the corneal epithelium and associated with disorganized epithelial cells and minimal leukocyte infiltrates. Subepithelial keratomycosis was correlated with focal, dense accumulations of hyphae in the immediate subepithelial anterior stroma. The hyphae were surrounded by moderate numbers of leukocytes. Two horses were examined by confocal microscopy on multiple occasions during the course of medical therapy and fungal hyphae were observed to migrate from the epithelium into the subepithelial stroma as the clinical corneal disease progressed. **Conclusions.** With *in vivo* confocal microscopy, both epithelial and subepithelial keratomycosis appear as unique clinical entities. Equine epithelial keratomycosis is a potential precursor to subepithelial keratomycosis. **None**.

INTRASTROMAL INJECTIONS OF 1% VORICONAZOLE AND REDUCTION IN TOPICAL TREATMENT FREQUENCIES TO TREAT ANTERIOR STROMAL KERATOMYCOSIS IN HORSES, (Fischer BM[1,2], McMullen Jr RJ[1,2], Rodriguez-Galarza RM[2], Beyer A[2]), [1]Equine Clinic Munich Riem, Munich, Germany; [2] Auburn University, College of Veterinary Medicine, Department of Clinical Sciences, Auburn, AL

Purpose. Present preliminary results of multifocal anterior stromal injections of 1% voriconazole to treat superficial keratomycosis. **Methods.** 15 adult horses of various breeds, age, and gender which were diagnosed with superficial keratomycoses (confirmed by cytology and/or cultures) were treated via anterior stromal injections of 1% voriconazole, subconjunctival 1% voriconazole injections and reduced frequency of topical antimicrobial therapy (voriconazole 1% q8-6h, and topical antibiotics q8h). Once the horses were sedated, local anesthesia was performed (retrobulbar and eyelid blocks) and the conjunctival sac was irrigated with a 1% povidone iodine solution. A 30 gauge needle attached to a 1 ml syringe was used to perform the multifocal intrastromal injections. A second needle-syringe combination was used to inject the subconjunctival 1% voriconazole. **Results.** 13/15 eyes resolved without incident within 4-weeks. Both of the remaining eyes were additionally treated with focal photodynamic therapy, using indocyanine green (EmunDo®) as the photosensitive agent and resolved without further incident. Although a large volume of voriconazole 1% (up to 1.0 ml) was diffusely injected, no complications, apart from occasional stromal fractures, observed following the introduction of air into the corneal stroma, were recorded. **Conclusions.** The use of anterior stromal injections of 1% voriconazole can be effectively used to treat superficial keratomycosis, while simultaneously reducing the frequency of topical medications. Further studies are required to evaluate corneal stromal drug levels and MIC's following intrastromal injections of 1% voriconazole. **None**

LOW-DOSE INTRAVITREAL INJECTIONS OF 4MG GENTAMICIN AND SUPERFICIAL LAMELLAR KERATECTOMY COMBINED WITH CONJUNCTIVAL ADVANCEMENT GRAFTS TO CONTROL CHRONIC HETEROCHROMIC IRIDOCYCLITIS AND SECONDARY KERATITIS (HIK): PRELIMINARY RESULTS (McMullen Jr RJ[1,2], Fischer BM[1,2]), [1]Equine Clinic Munich Riem, Munich, Germany; [2] Auburn University, College of Veterinary Medicine, Department of Clinical Sciences, Auburn, AL

Purpose. Describe a novel, combined approach to manage chronic heterochromic iridocyclitis and secondary keratitis (HIK), which often leads to blindness and/or enucleation. **Methods.** 9 eyes from 8 adult horses of various breeds (5 Warmbloods, 1 Quarter horse, 1 PRE, and 1 Standardbred), age (range 6-26 years; 15.875 ± 1.43 years), and gender (4 mares, 3 geldings, and 1 stallion) diagnosed with HIK were treated with low-dose intravitreal gentamicin (IVG) injections (4 mg) and modified Gundersen flaps (1 or 2 elliptical superficial lamellar keratectomies and sliding conjunctival hood grafts fixated with 8-0, 910 polyglactin sutures) under standing sedation and local anesthesia (eyelid and retrobulbar blocks) using loupes (2.3x, Zeiss, Jena) for magnification. One horse also received bilateral cyclosporine implants (each eye on separate days) during the same sedation. **Results.** Postoperative treatment consisted of topical bromfenac and antibiotics and systemic flunixin-meglumine (1.1 mg/kg PO, q24h). Perilesional corneal edema developed 3-5 days postoperatively, which gradually resolved over several weeks. Postoperative inflammation (uveitic component) was controlled in all of the horses. Corneal edema and associated opacification was reduced to various degrees in all eyes. Complications included chronic corneal ulceration (1/9, 11.1%), recurrent corneal edema (4/9, 44.4%), and increased photophobia (2/11, 18.2%). **Conclusions.** The combined treatment protocol described herein has effectively helped to manage this enigmatic disease and prevented enucleation in all of the horses in this study. Further long-term follow-up is necessary. **None**

EVALUATION OF INTERLEUKIN-6 EXPRESSION IN AN *EX VIVO* MODEL OF EQUINE CORNEAL WOUND-HEALING (G Ben-Shlomo, and RF Wehrman) Department of Veterinary Clinical Sciences, College of Veterinary Medicine, Iowa State University.

Purpose. To evaluate interleukin-6 (IL-6) expression in an ex vivo model of equine corneal wound healing. **Methods.** Fourteen equine corneas were harvested within two hours of humane euthanasia for reasons unrelated to the study. Eight and six corneas were assigned to a wounded or an unwounded control group, respectively. Corneoscleral rims were excised 2mm posterior to the limbus. Central corneal ulcer was created by applying a 6mm filter paper disk soaked in 1N-NaOH for 60 seconds. Corneas were cultured using an air-liquid interface model. The rocker was set to bathe the cornea 8 times per minute, and the corneal ulcers were measured daily. Corneas were submitted for histologic evaluation and RNAscope *in situ* hybridization for evaluation of IL-6 expression at 24, 48 and 72 hours. The expression of IL-6 was scored per RNAscope manufacturer guidelines. **Results.** All corneal ulcers healed within 72 hours. All corneas in both the experimental and control groups maintained normal architecture and minimal stromal edema. The average IL-6 expression score for wounded corneas was 1.7, 0.93, and 0.2 for T24, T48, and T72 respectively. The greatest amount of IL-6 expression was noted in the basal epithelial layer closest to the wound margin. The average score for unwounded corneas was 0.3 for T24, and 0 for T48 and T72. **Conclusions.** Interleukin-6 expression increases in wounded equine corneas compared to unwounded ones, with the greatest amount in the basal epithelial layer, close to the wound margin. Interleukin-6 expression decreases as the corneal healing progresses. Supported partially by Iowa State University, Department of Veterinary Clinical Sciences and the American Quarter Horse Foundation. **None.**

COMPARATIVE ANALYSIS OF FUNGAL GENOMES OF ISOLATES FROM EQUINE KERATITIS (M Jacob,[1] M Cubeta,[2] I Carbone,[2] and B Gilger [3]) Population Health and Pathobiology, College of Veterinary Medicine, NCSU;[1] Center for Integrated Fungal Research, College of Agriculture and Life Sciences, NCSU;[2] Clinical Sciences, College of Veterinary Medicine, NCSU.[3]

Purpose. To characterize the virulence potential and antifungal susceptibility of specific causative fungal isolates early in the course of fungal keratitis. **Methods.** Morphological characterization and genome sequencing of 14 fungal isolates from clinical cases of fungal keratitis presented to the NCSU-VTH Equine Ophthalmology Service was performed. Association of fungal DNA diversity with clinical and environmental factors was evaluated with a high-performance computing cluster tool using Mobyle SNAP Workbench. Reference phylogenies from O'Donnell et al 2016 and Carbone et al (unpublished) were used to evaluate fungal-isolate disease aggressiveness**.** **Results.** Phenotypically, *Aspergillus* and *Fusarium* were the predominate fungi isolated from infected horse eyes and identification was confirmed by DNA sequence analysis. Three distinct multi-locus haplotypes of *Fusarium* were identified from five equine isolates that belonged to either the *Fusarium solani* or *Fusarium fujikuroi* species complexes. All *Aspergillus* equine isolates were placed in two distinct lineages of *Aspergillus flavus* based on multiple loci. Nonaflatoxigenic strains of *A. flavus* strains was their nearest common ancestor. In both *Aspergillus* and *Fusarium* isolates, there was genetic differentiation that associated with isolate aggressiveness. **Conclusions.** Although the sample size was small, there is compelling evidence of fungal species/lineage specific differences in fungal keratitis severity. Supported: NC State Univ. **None**.

EQUINE INTRAOCULAR MELANOCYTIC TUMORS TREATED WITH STANDING DIODE LASER PHOTOCOAGULATION AND CONCURRENT XENOGENEIC TYROSINASE VACCINE: ONE YEAR OUTCOME (M Lassaline, B Vaughan, MB Whitcomb, KE Knickelbein) Department of Surgical & Radiological Sciences, University of California, Davis, CA.

The clinical and histopathologic characteristics of equine intraocular melanocytic tumors have been described, but treatment outcomes have not been definitively determined. The effect on intraocular melanocytic tumors of a xenogeneic tyrosinase vaccine used to treat cutaneous melanoma in horses has not been described. **Purpose.** To evaluate the utility of diode laser photocoagulation as a noninvasive, globe- and vision-sparing treatment for intraocular melanocytic tumors, and to describe concurrent therapy with a xenogeneic tyrosinase vaccine, in horses with comorbid cutaneous melanoma. **Method.** A retrospective medical record review included horses meeting criteria (1) diagnosis of intraocular melanocytic tumor by a veterinary ophthalmologist and (2) treatment with diode laser photocoagulation, and included variables (1) patient signalment, (2) age at diagnosis and treatment, (3) laser treatment protocol, (4) preoperative and postoperative tumor measurement from photographs and ultrasound imagery, (5) length of follow-up and (6) outcome, classified as decreased, no change or increased in size. **Results.** Four horses met inclusion criteria. All were gray in color, with breeds including Thoroughbred, Kentucky Mountain Horse, and Hungarian Warmblood, and age at presentation ranging from 6-21 years. Three have been enrolled in a tyrosinase vaccine trial. No intraocular lesions completely regressed but all were classified as static or smaller, with comfortable visual globes requiring minimal treatment at last follow up (median = 408 days). **Conclusions.** Diode laser photocoagulation may be a viable noninvasive, economical globe- and vision-sparing therapeutic option for horses with intraocular melanocytic tumors. The impact of concurrent treatment with the tyrosinase melanoma vaccine is unknown. **None.**

Modified Medial Canthoplasty in a 20-year old Shetland Pony Mare with Lagophthalmos After Chronic Eyelid Laceration

Author and Address:
Blohm, KO; Nell, B
University of Veterinary Medicine Vienna, 1210 Vienna, Austria

Topic Area:
Adnexa

Case Summary:
A 20-year-old Shetlandpony mare was presented to our Ophthalmology Service for lagophthalmos of the right eye, subsequent chronic keratitis, corneal neovascularisation and fibrosis. Sequelae of a laceration injury inhibited eyelid closure and caused corneal-, conjunctival- and lacrimal caruncle exposure. The horse exhibited restricted palpebral nerve- and orbicularis oculi muscle function due to extensive periocular scar tissue formation. Partial loss of superior, medial and inferior eyelid margins deteriorated the situation.
Medial canthoplasty was performed under regional anaesthesia in standing sedation. Perioperative medication included oral flunixin meglumine (1,1 mg/kg SID) and omeprazole (2 mg/kg SID). Despite temporary tarsorrhaphy primary surgical wound became dehiscent six days postoperatively accompanied by blepharospasm and purulent discharge. After wound debridement a second suture approach was accomplished to attach the inferior eyelid to the medial canthus. Apposition of the superior eyelid was relinquished due to traction forces rather aiming for secondary granulation of the upper medial canthus. Oral trimethoprim/sulfadiazin (30 mg/kg BID) and topical chloramphenicol ointment (TID) were added to treatment. Seven days after surgical revision the mare was discharged. At the time of submission follow-up examinations at day 21 and 50 after initial eyelid reconstruction revealed resolved lagophthalmos. The eye is sighted without signs of irritation.

Key Words:
Eyelid laceration, posttraumatic cicatrization, lagophthalmos, medial canthoplasty, complication

Discussion Points:
Possibility of H-plasty/advancement eyelid flap or skin graft in this case?
Is a third surgery for repositioning of prolapsed conjunctiva from superior palpebral fornix recommended?
Does the initial surgical procedure as described necessitate peri- or postoperative systemic antibiotic treatment?

Figure 1. Exposure of the cornea, conjunctiva and lacrimal caruncle combined with partial loss of the superior, medial and inferior eyelid margins.

Figure 2. Initial medial canthoplasty.

Figure 3. Fourty-four days after second surgery.

Lateral Canthoplasty to Facilitate Wide Resection of Eyelid Tumors

Author and Address:
Nunnery, C
Equine Veterinary Vision, Inc. Alexandria, VA 22315

Topic Area:
Adnexa

Case Summary:
A case series of seven patients with eyelid neoplasia that received lateral canthal reconstruction to facilitate the closure of the wide mass resection. The neoplastic mass was resected with 1-5mm margins using the four-sided house technique. A full thickness lateral canthotomy was performed, then sharp dissection through the thick periorbital fascia near the orbital rim facilitated loosening the attachment of lateral eyelid. The margin defect was then closed in a two-layer fashion with a buried figure of eight. The new canthus was closed opposing the existing lateral canthal margin to the mid-section of cut skin edge. In some, the closure resulted in a skin fold that was excised and closed. The last step was to trim down the end of the lateral canthus now in the lateral third of the margin. All horses received oral antibiotics with NSAIDs and some received topical antibiotics. All patients healed with a new mucocutaneous eyelid margin and most horses retained a normal size and shape palpebral fissure. Complications including dehiscence, infection and corneal ulceration all healed with medical therapy. No recurrence of the neoplasia has been reported, but all are less than two years post-op.

Key Words:
Eyelid, Neoplasia, Lateral Canthoplasty

Discussion Points:
Tight palpebral fissure stretches? Tarsorrhaphy affect?
New mucocutaneous junction eyelid margin? Trichiasis?
Wider margins around tumor decrease recurrence?

Figure 1- Wide four-sided house resection of eyelid mass.

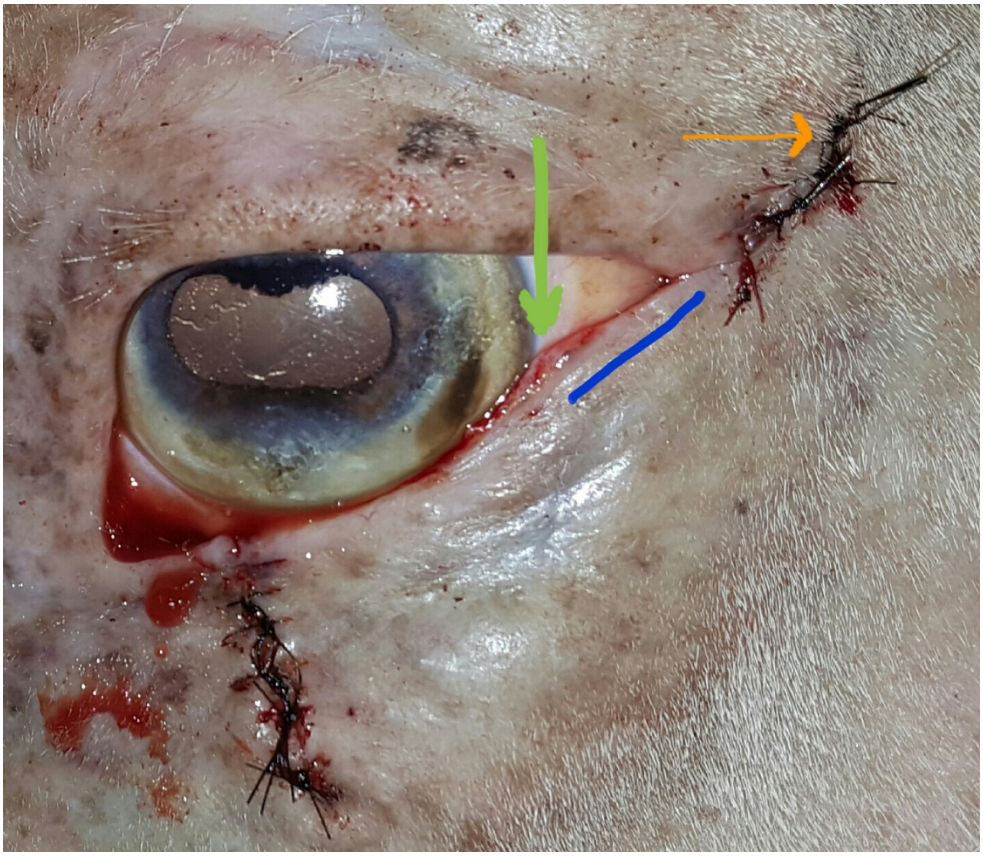

Figure 2- Closure of eyelid margin and lateral canthoplasty incisions. Blue line is the length of the new lateral eyelid margin, green arrow is the location of the lateral canthal bump that has been trimmed and the orange arrow is the skin fold resection.

Figure 3. Three weeks post-op the incisions are healed new margin is functional and cosmetic. Wound at the margin incision is from removing a deep suture tag that was missed at 2-week suture removal.

Enophthalmos and Restrictive Strabismus in a Connemara Gelding

Authors and Addresses:
Rachel Allbaugh*, DVM, MS, DACVO, Rachel Strauss*, VMD (Resident) and Ellison Bentley^, DVM, DACVO *Iowa State University Department of Veterinary Clinical Sciences, Ames, IA 50011^ University of Wisconsin-Madison School of Veterinary Medicine, Madison, WI 53706

Topic Area:
Globe/Orbit

Case Summary:
An 18-year-old Connemara gelding presented to the University of Wisconsin-Madison with a 6-month history of right third eyelid elevation and decreased ocular motility (Figures 1 and 2). Skull radiographs and orbital ultrasound were unremarkable, and no improvement was seen with systemic nonsteroidal anti-inflammatory drugs or antibiotics so he was referred to Iowa State University for advanced imaging. A CT scan was performed and showed normal globes and periocular structures. While still under anesthesia, minor surgery was elected and the right lateral rectus muscle was transected blindly. After the lateral rectus muscle was cut, the eye appeared to return to a more central location, but remained mildly enophthalmic. Though the lateral rectus muscle could not be visually assessed during surgery, the dorsal rectus muscle was viewed and appeared normal, while the ventral oblique muscle appeared visually abnormal with a pale gray/white color and greater compliance than normal extraocular muscles. A ¼ thickness biopsy was obtained of the ventral oblique muscle and submitted for histopathology, but was reported to be normal appearing skeletal muscle with no evidence of myodegeneration, fibrosis, inflammation or neoplasia. Postoperativey the eye remained in the improved position (Figure 3) for a few months then lateral strabismus gradually recurred.

Key Words:
Strabismus, enophthalmos, third eyelid elevation, and extraocular muscle

Discussion Points:
1. Other known cases of restrictive strabismus in a horse?
2. Thoughts on additional surgery?

Images:
Clinical appearance of the patient's right eye before and after surgery.
Figure 1. Image of the 18-year-old Connemara gelding at initial presentation with right globe deviation and third eyelid elevation visible.

Figure 2. Up-close image of the same horse highlighting right eye strabismus.

Figure 3. Image of the same horse 1 week postoperatively with improved globe orientation and reduced third eyelid elevation.

Traumatic Extrusion of the Lens to the Episcleral Space

Author and Address:
Knickelbein, KE; Lassaline ME; Reilly, CM
University of California at Davis, Davis, CA 95616

Topic Area:
Lens

Case Summary:
An 18-year-old American Miniature Horse mare was presented to the UC Davis Ophthalmology Service for persistent blepharospasm and a subconjunctival swelling of the right eye following suspected trauma 6 weeks prior. Clinical findings included severe blepharospasm, a bulbous, spherical swelling of the dorsotemporal bulbar conjunctiva, and intraocular findings consistent with phthisis bulbi. Standing enucleation of the right globe was performed. Gross and histopathologic examination of the globe was consistent with extrusion of the lens to the episcleral space.

Key Words:
Trauma, globe rupture, lens extrusion

Discussion Points:
Lens extrusion with retention in the periocular tissues
Most common sites of traumatic rupture of the globe
Ophthalmic examination findings following blunt trauma

Figure 1. Clinical image revealing subconjunctival swelling and phthisis bulbi OD.

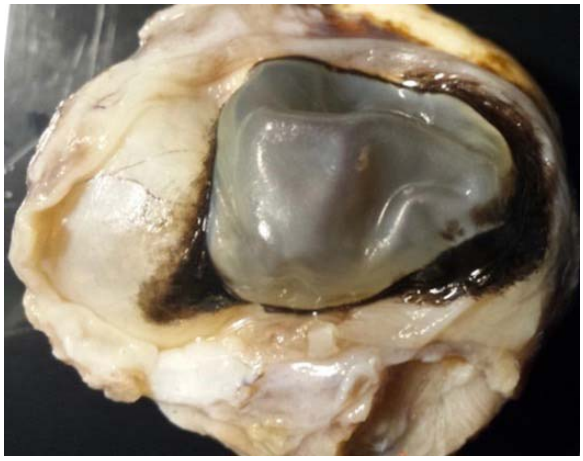

Figure 2. Gross image following enucleation revealing the lens to be entrapped under the conjunctiva OD.

Triple Ostectomy Orbitectomy in a Horse for Retrieval of a Foreign Body at the Coronoid Process Diagnosed with an MRI

Authors and Addresses:
T. Launois[1], ECVS, DESV 1, DE.O, J. M Vanderweerd DECVS 2, G. Lane[3] DESTS FRCVS, D. Gorgas[4] ECVID 1 Clinique du Lys – Bailly Vétérinaires – 663 avenue Jean Jaurès – 77190 Dammarie les Lys 2 Service d'Anatomie Vétérinaire, Université de Namur**,** Rue de Bruxelles, 61, 5000 Namur, Belgium, 3 The Cedars Cross AXBRIDGE Somerset BS26 2EG, United Kindom, 4 Universität Bern Vetsuisse Fakultät Departement für klinische Veterinärmedizin Abteilung für klinische Radiologie. Switzerland

Topic Area:
Orbit, MRI, Foreign Body.

Case Summary:
A 3 years old French Selle - Français Race Horse (AQPS) gelding was presented with an upper lid fistula still draining despite debridement by the referring veterinary surgeon one month ago for a foreign body. At the examination, the horse presented an upper lid fistula of his left eye. X-rays were unremarkable and ultrasound examination indicated an intraorbital foreign body. The horse was operated under general anesthesia with the goal of removing the foreign body by following the fistula posteriorly. The orbital septum was opened to get access to the posterior orbit, however no foreign body was found. Post – operatively the fistula healed but the eye was still discharged. It was advised to perform an MRI, which revealed a foreign body at the pterygoid process. A second surgery was done under general anesthesia, with a triple ostectomy of the zygomatic bone to access to the pterygoid process. It was not possible to find any foreign body. The surgical site was irrigated saline under endoscopic control. The zygomatic bone was not used to closed the orbit, the periosteum was closed, the sub – cutaneous tissue and the skin were sutured. The Horse did heal in one week without any recurrence. The horse has been followed for four years and at April 2017, is doing fine.

Discussion Points:
Should we have done the MRI sooner?
Would have been an enucleation an option?
Would you have used another surgical approach? Another surgical technique?

Photos (see next page):

Fig 1: MRI showing the foreign body.


Fig 2: Anatomic specimen showing the foreign body's position.

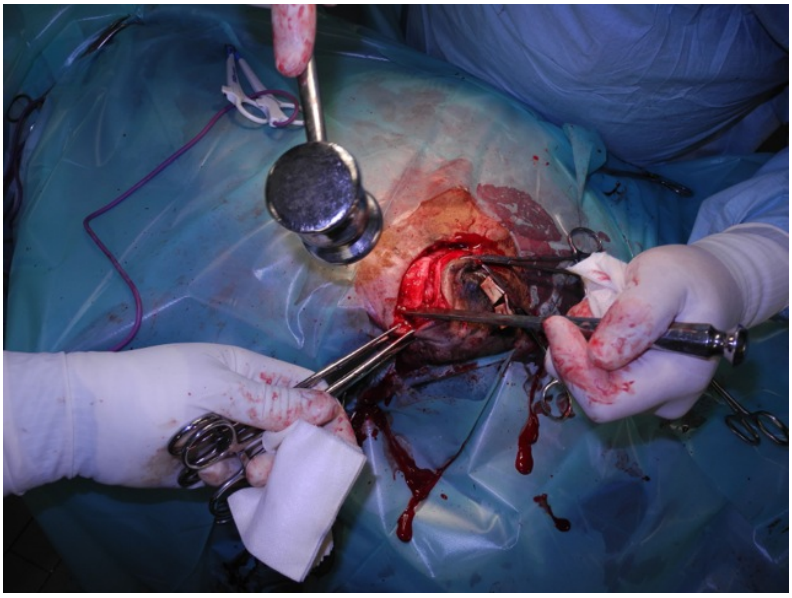
Fig. 3: Ostectomy of zygomatic bone.


Fig 4: Post-operative appearance at 3 weeks.

Periocular Neomycin Reaction in an Appaloosa

Authors and Addresses:
Pryor, S; Czerwinski S; Diehl, K; Myrna, K
University of Georgia, Athens, GA 30602

Topic Area:
Adnexa

Case Summary:
A 14-y.o Appaloosa mare presented for uveitis OD of 4 months duration. At presentation, the patient was on diclofenac OD BID. The periorbital skin and adnexa were normal OU. OU were comfortable; OD was blind, OS had an intermittent menace secondary to complete and incomplete cataracts respectively. Remaining findings included keratitis, uveitis, a smooth and hyperpigmented iris, posterior synechia OU. Ocular ultrasound was not performed. ERU was diagnosed and medical management was elected. Diclofenac was increased to QID and NeoPolyDexamethasone ointment QID was added. Fourteen days later the owner noted changes of the inferior eyelid (Fig 1). At 28d recheck, both eyelids were alopecic with pigmentary changes (Fig 2). Biopsies of the more severely affected right eyelids and NeoPolyDex was discontinued as the lesions occurred after starting this medication. Dermatohistopathology revealed mild chronic diffuse dermatitis. 35 days later, while only on diclofenac, the lesions resolved (Fig 3).

Key Words:
Adnexa, periocular, dermatitis, topical, neomycin

Discussion Points:
Periocular and adnexal lesions without ocular reactions with NeoPolyDex
Diagnosis of skin irritants
Treatment of adnexal contact dermatitis/neomycin/polymixin B reaction?

Figure 1: Patient 4 days after NeoPolyDex.

Figure 2: Progressive periocular and adnexal alopecia and pigmentary changes 24 days after NeoPolyDex.

Figure 3: Periocular and adnexal lesions resolved 35 days after stopping NeoPolyDex.