IEOC/TONOVET Equine Ophthalmology Symposium

The Radisson Blu Saga Hotel
Reykjavik, Iceland

June 7-9, 2018

International Equine Ophthalmology Consortium
PO Box 1311 Meridian ID 83680 | 208-466-2519 | office@equineophtho.org

IEOC/TONOVET Equine Ophthalmology Symposium

June 7-9, 2018

The Radisson Blu Saga Hotel | Reykjavik, Iceland

The goal of this symposium is to share, with a small group of dedicated clinicians and scientists, current clinical and basic research on equine ophthalmology. Abstract and case presentations, along with social events, will facilitate the development of multi-centered collaborative research.

This symposium is sponsored by:

icare TONOVET

www.tonovet.com

Sponsors

NAMESAKE SPONSOR

Icare Findland Oy

www.tonovet.com

Icare Finland is a healthcare technology company, which produces advanced, hand-held tonometers measuring IOP by unique, patented rebound technology. Icare rebound tonometers are proven accurate, easy to use and patient-friendly by several independent clinical studies and tens of thousands satisfied users worldwide. For the past few years Icare has strongly invested resources into the veterinary segment to be able to supply a true veterinary tonometer for this market's special needs. Last year we launched the new Icare **TONOVET Plus** tonometer, which has new features that make IOP measuring even easier and more accurate with new calibrations for the dog, cat, rabbit and **horse** - still without calibration or anesthesia.

SPONSOR, STATE OF THE ART LECTURERS

an-vision, Inc.

www.an-vision.com

Our founders have decades of combined experience in the industry in the design and manufacturing of cutting edge intraocular lenses, corneal lenses, viscoelastics, and other surgical equipment and products specifically designed for the veterinary ophthalmologist. To follow our vision, we established two companies, **an-vision GmbH** in Germany and **an-vision Inc** in Salt Lake City, Utah.

2018 IEOC/TONOVET SYMPOSIUM PROGRAM

Time	Room	Event	Presenter	Title/Topic
Thursday, June 7				
6:00pm-8:00pm	Sulnasalur Ballroom	Welcome Reception/Registration ***Attendee name badge required/guest ticket required.***		
Friday, June 8				
7:00am		Registration desk open		
7:30am-8:30am	***Heckla and Esja rooms***	***Breakfast Buffet*** ***Note: The same breakfast buffet will be available in both adjacent rooms.***		
8:30am-8:45am	Katla	Welcome and Introduction	B. Patterson	
8:45am-9:45am	Katla	State of The Art Lecture	Dr. Eric Ledbetter	"Advanced Imaging of the Equine Eye"
9:45am-10:00am	***Heckla***	***Beverage Break (no food)***		
10:00am-11:00am	Katla	State of the Art Lecture	Dr. Eric Ledbetter	"Advanced Imaging of the Equine Eye"
11:00am-12:00pm	**Scientific Abstract Presentations**		**Moderator**	*15 minute presentations, 5 minute Q&A*
11:00am	Katla		Z. Makra	COMPARISON OF THE EFFECT OF INTRAVENOUS FLUNIXIN MEGLUMINE, PHENYLBUTAZONE AND ELECTROACUPUNCTURE ON OCULAR PAIN IN THE HORSE: A PILOT STUDY
11:20am	Katla		M. Huck-Miller	HOW TO USE IV TUBING AS PROTECTIVE CONDUIT OVER SUBPALPEBRAL LAVAGE
11:40am	Katla		T. Knott	3D PRINTED EQUINE TRAINING EYE. DESIGN AND USE FOR TEACHING OPHTHALMOSCOPY, SLIT LAMP BIOMICROSCOPY AND OCULAR PHOTOGRAPHY
12:00pm-1:00pm	***Heckla and Esja***	***Lunch Buffet (Attendees only) name badge required.*** ***Note: The same lunch buffet will be available in both adjacent rooms.***		
1:00pm-2:00pm	**Scientific Abstract Presentations**		**Moderator**	*15 minute presentations, 5 minute Q&A*
1:00pm	Katla		L. Sandmeyer	RISK FACTORS FOR ERU IN A POPULATION OF APPALOOSA HORSES IN WESTERN CANADA
1:20pm	Katla		L. Sandmeyer	ERU IN A POPULATION OF PONY OF THE AMERICAS IN THE USA
1:40pm	Katla		B. Gilger	ACUTE AND CHRONIC RESPONSE TO SUPRACHOROIDAL TRIAMCINOLONE FOR TREATMENT OF POORLY-RESPONSIVE UVEITIS
2:00pm-2:15pm	***Heckla***	***Beverage Break***		
2:15pm-3:15pm	**Case Reports**		**Moderator**	*10 minute presentations, 5 minute discussion*
2:15pm	Katla		C. Plummer	Image-Guided Intervention for Correction of Nasolacrimal Atresia
2:30pm	Katla		L. Pelych	Radical Exenteration on Recurrent Equine Squamous Cell Carcinoma (SCC) of the Eyelid and Periorbital Region

Time	Room	Event	Presenter	Title/Topic
Friday, June 8 Continued				
2:45pm	Katla		L. Sandmeyer	Piroxicam Treatment for Eyelid Squamous Cell Carcinoma in Two Horses
3:00pm	Katla		T. Launois	Orbitoscopy in a Horse with an Osseous Orbital Wound
3:15pm-4:15pm	Katla			"Hot Topics" Discussion
4:15pm	Conclude			
4:45pm-5:00pm	***Attendees Load Busses for Horse Show and Dinner (ticket is required)***			
5:00pm-5:15pm	***Travel to Horse Show***			
5:30pm-6:15pm	***Horse Show at Reiðhöllin í Viðidal***			
6:15pm-6:30pm	***Attendees Load Busses for Dinner***			
6:30pm-7:15pm	***Travel to Dinner at Fjorubordid Restaurant***			
7:30pm-9:30pm	***Dinner at Fjorubordid Restaurant***			
9:30pm	***Attendees load Busses for Return Trip to Hotel (approx. 1 hour travel)***			

Time	Room	Event	Presenter	Title/Topic
Saturday, June 9				
7:00am-8:00am	***Heckla and Esja***	***Breakfast Buffet*** ***Note: The same breakfast buffet will be available in both adjacent rooms.***		
6:30am		Registration Desk Open		
8:00am-8:15am	Katla	Speaker Introduction	B. Patterson	
8:15am-9:15am	Katla	State of the Art Lecture	Dr. Rebecca Bellone	"Seeing Equine Ocular Disorders thru a DNA Lens: Utilizing DNA Testing to Inform Clinical Management Decisions"
9:15am-9:30am	***Heckla***	***Beverage Break***		
9:30am-10:30am	Katla	State of the Art Lecture	Dr. Rebecca Bellone	"Seeing Equine Ocular Disorders thru a DNA Lens: Genetic Studies Underway"
10:30am-11:50am	**Scientific Abstract Presentations**		**Moderator**	*15 minute presentations, 5 minute Q&A*
10:30am	Katla		B. Gilger	ASSOCIATIONS AMONG ANTI-FUNGAL SUSCEPTIBILITY, MULTI-LOCUS SEQUENCE ANALYSIS, AND CLINICAL OUTCOME IN EQUINE FUNGAL KERATITIS
10:50am	Katla		R. Allbaugh	EVALUATION OF VORICONAZOLE CONCENTRATIONS IN EQUINE TEARS FOLLOWING SUBCONJUNCTIVAL INJECTION OF CONCENTRATED ANTIFUNGAL COMBINED WITH THERMOSENSITIVE POLOXAMER GEL
11:10am	Katla		V. Prucha	EQUINE SUPERFICIAL NON-HEALING CORNEAL ULCERS: A RETROSPECTIVE EVALUATION OF 58 CASES (2001-2017)

Time	Room	Event	Presenter	Title/Topic
Saturday, June 9 Continued				
11:30am	Katla		J. Meekins	THE EFFECT OF BODY POSITION ON INTRAOCULAR PRESSURE IN ANESTHETIZED HORSES
11:50am-1:00pm	***Heckla and Esja rooms***	***Lunch Buffet (Attendees only) name badge required.*** ***Note: The same lunch buffet will be available in both adjacent rooms.***		
1:00pm-2:15pm	**Case Reports**		**Moderator**	*10 minute presentations, 5 minute Q&A*
1:00pm	Katla		M. Voyles	Corneal Hemangiosarcoma in a 27 Year-Old Arabian Gelding. Treatment and One Year Follow-Up
1:15pm	Katla		C. Plummer	Resolution of Recurrent DSA with Surgical Excision in Two Horses
1:30pm	Katla		K. McGovern	Lamellar Defect in the Posterior Cornea of a 2 Year-Old Thoroughbred Filly
1:45pm	Katla		A. Dwyer	Immune Mediated Keratitis in a Thoroughbred Gelding
2:00pm	Katla		H. Hermans	Bilateral Corneal Stromal Loss in a 24-year-old Haflinger Mare
2:15pm	Katla		U. Dietrich	Spontaneous Healing of a Traumatic Lens Capsule Rupture in a Horse
2:30pm-2:45pm	***Heckla***	***Beverage Break***		
2:45pm-3:30pm	**Case Reports**		**Moderator**	*10 minute presentations, 5 minute discussion*
2:45pm	Katla		E. Scott	Trabecular Meshwork Fibrosis Associated with Primary Glaucoma in an Adult Lipizzaner Gelding
3:00pm	Katla		W. Townsend	Primary Glaucoma in a Horse
3:15pm	Katla		Z. Makra	Post-Anaesthetic Central Blindness in a Stallion
3:30pm-4:30pm	Katla			"Hot Topics" Discussion
4:30pm-5:00pm	**Katla**	**IEOC Member Business Meeting** Agenda emailed to members pre-symposium. All registered attendees are members, please attend.		
5:00pm	**Adjourn**			
5:00pm-6:00pm	**TBD**	**IEOC Board Meeting**		

IEOC/TONOVET SYMPOSIUM INDEX
LISTED IN ORDER OF PRESENTATION

Program schedule……. Page 2

Friday, June 8th
State of the Art Lecturer, Dr. Eric Ledbetter……..…….. Page 7
"Advanced Imaging of the Equine Eye"

Abstracts

Author	Title	
Z. Makra	"COMPARISON OF THE EFFECT OF INTRAVENOUS FLUNIXIN MEGLUMINE, PHENYLBUTAZONE AND ELECTROACUPUNCTURE ON OCULAR PAIN IN THE HORSE: A PILOT STUDY"	Page 13
M. Huck-Miller	"HOW TO USE PLASTIC IV TUBING AS PROTECTIVE CONDUIT OVER SUBPALPEBRAL LAVAGE TUBING"	Page 14
T. Knott	"3D PRINTED EQUINE TRAINING EYE. DESIGN AND USE FOR TEACHING OPHTHALMOSCOPY, SLIT LAMP BIOMICROSCOPY AND OCULAR PHOTOGRAPHY"	Page 15
L. Sandmeyer	"RISK FACTORS FOR ERU IN A POPULATION OF APPALOOSA HORSES IN WESTERN CANADA"	Page 16
L. Sandmeyer	"ERU IN A POPULATION OF PONY OF THE AMERICAS IN THE USA"	Page 17
B. Gilger	"ACUTE AND CHRONIC RESPONSE TO SUPRACHOROIDAL TRIAMCINOLONE FOR TREATMENT OF POORLY-RESPONSIVE UVEITIS"	Page 18

Case Reports

Author	Title	
C. Plummer	Image-Guided Intervention for Correction of Nasolacrimal Atresia	Page 19
L. Pelych	Radical Exenteration on Recurrent Equine Squamous Cell Carcinoma (SCC) of the Eyelid and Periorbital Region	Page 21
L. Sandmeyer	Piroxicam Treatment for Eyelid Squamous Cell Carcinoma in Two Horses	Page 23
T. Launois	Orbitoscopy in a Horse with an Osseous Orbital Wound	Page 25

Saturday, June 9th

State of the Art Lecturer, Dr. Rebecca Bellone…….. Page 28
"Seeing Equine Ocular Disorders thru a DNA Lens: Utilizing DNA Testing to Inform Clinical Management Decisions", and "Seeing Equine Ocular Disorders thru a DNA Lens: Genetic Studies Underway"

Abstracts

Author	Title	
B. Gilger	"ASSOCIATIONS AMONG ANTI-FUNGAL SUSCEPTIBILITY, MULTI-LOCUS SEQUENCE ANALYSIS, AND CLINICAL OUTCOME IN EQUINE FUNGAL KERATITIS"	Page 33
R. Allbaugh	"EVALUATION OF VORICONAZOLE CONCENTRATIONS IN EQUINE TEARS FOLLOWING SUBCONJUNCTIVAL INJECTION OF CONCENTRATED ANTIFUNGAL COMBINED WITH THERMOSENSITIVE POLOXAMER GEL"	Page 34
V. Prucha	"EQUINE SUPERFICIAL NONHEALING CORNEAL ULCERS: A RETROSPECTIVE EVALUATION OF 58 CASES (2001-2017)"	Page 35
J. Meekins	"THE EFFECT OF BODY POSITION ON INTRAOCULAR PRESSURE IN ANESTHETIZED HORSES"	Page 36

Case Reports

Author	Topic	
M. Voyles	Corneal Hemangiosarcoma in a 27 Year Old Arabian Gelding. Treatment and One Year Follow Up	Page 37
C. Plummer	Resolution of Recurrent DSA with Surgical Excision in Two Horses	Page 39
K. McGovern	Lamellar Defect in the Posterior Cornea of a 2 Year Old Thoroughbred Filly	Page 41
A. Dwyer	Immune Mediated Keratitis in a Thoroughbred Gelding	Page 43
H. Hermans	Bilateral Corneal Stromal Loss in a 24-Year-Old Haflinger Mare	Page 44
U. Dietrich	Spontaneous Healing of a Traumatic Lens Capsule Rupture in a Horse	Page 47
E. Scott	Trabecular Meshwork Fibrosis Associated with Primary Glaucoma in an Adult Lipizzaner Gelding	Page 50
W. Townsend	Primary Glaucoma in a Horse	Page 52
Z. Makra	Post-Anaesthetic Central Blindness in a Stallion	Page 54

State of the Art Lecturer

Dr. Eric Ledbetter

DVM, DACVO
Associate Professor
Cornell University-Hospital for Animals
Ithaca, NY

Dr. Ledbetter is a Diplomate of the American College of Veterinary Ophthalmologists and an Associate Professor of Ophthalmology at the Cornell University College of Veterinary Medicine. After graduating from the University of Missouri, College of Veterinary Medicine, he completed a small animal medicine and surgery internship at Texas A&M University College of Veterinary Medicine and a comparative ophthalmology residency at Cornell University, where he joined the faculty in 2006.

Dr. Ledbetter's research interests include *in vivo* ocular imaging techniques, ocular infectious disease, and corneal disease. In addition to research and teaching endeavors, Dr. Ledbetter provides clinical ophthalmology services within Cornell University's Companion Animal and Equine & Farm Animal Hospitals.

Sponsored by:

an-vision

Advanced Imaging of the Equine Eye

Eric C. Ledbetter, DVM, DACVO
Associate Professor of Ophthalmology
Department of Clinical Sciences
Cornell University, College of Veterinary Medicine, Ithaca, NY 14850 USA
ecl32@cornell.edu

Introduction

Ophthalmic imaging techniques available for use in equine medicine have rapidly expanded in recent years. Use of these newer imaging modalities has permitted observation of anatomical and physiologic changes associated with many equine ocular disorders in a manner that was not previously feasible or only possible with invasive sample collection techniques and laboratory analysis. Observations made with advanced imaging techniques have directly contributed to an improved understanding of many equine ocular conditions. When applied in the clinical setting, advanced ophthalmic imaging techniques have the potential to improve the clinical detection, diagnosis, and treatment of many equine ocular diseases.

This discussion will review the indications and techniques for advanced ophthalmic diagnostic imaging of the horse. Select advanced ocular imaging technologies available for use in the horse, including *in vivo* confocal microscopy, ocular coherence tomography, specular microscopy, infrared thermography, and infrared photography, will be discussed.

In vivo confocal microscopy

With conventional light microscopy techniques, including slit-lamp biomicroscopy, image magnification and resolution is limited by light reflected from tissue structures adjacent to the field of observation that obscures and reduces image contrast. All confocal microscopes utilize illumination and observation systems with a common focal point. These microscopes suppress reflected light originating outside the field of observation so that only light reflected from the specific focal plane of interest contributes to the final image formation. The net result of confocal microscopy systems is improved axial and lateral resolution, increased image contrast, and the achievement of higher magnification.

In vivo confocal microscopy of the cornea is uniquely possible because of the optical clarity of corneal tissues. In addition, optical adjustment of the focal plane of the *in vivo* confocal microscope permits visualization at different depths of the cornea. The three basic types of *in vivo* corneal confocal microscopes in clinical use are the tandem scanning-based confocal microscopes, scanning slit confocal microscopes, and laser scanning confocal microscopes. Of these, laser scanning confocal microscopy has been reported most commonly in clinical veterinary medicine.

The equine cornea is described to have 10 morphologically distinct layers when evaluated by *in vivo* confocal microscopy. From anterior-to-poster, these corneal layers are the superficial epithelial cells, superficial-intermediate epithelial cells, deep-intermediate epithelial cells, basal epithelial cells, basement membrane, anterior stroma, midstroma, deep stroma, Descemet's membrane, and corneal endothelium. The epithelial layers are distinguished by cell morphology, size, and density. The corneal stroma is composed of extracellular matrix and collagen lamellae that are nearly transparent and dark gray or black in color with

scattered keratocytes. Keratocytes have highly reflective round-to-oval nuclei with variably visible grey cytoplasm and cellular borders. In general, keratocyte density decreases from anterior-to-posterior within the equine cornea. Descemet's membrane has an amorphous or fine granular appearance with a uniform, moderate reflectivity. The healthy equine corneal endothelium is a confluent monolayer of hexagonal and pentagonal cells with highly reflective cytoplasm, dark cellular borders, and no visible nuclei. Additional structures observed in the normal equine cornea with *in vivo* confocal microscopy are corneal nerves and occasional Langerhans cells and corneal stromal dendritic cells.

Clinical applications of *in vivo* confocal microscopy in equine ophthalmology are numerous. *In vivo* confocal microscopy is a rapid and non-invasive method for diagnosing fungal keratitis in the horse. Ulcerative and nonulcerative keratomycosis can be evaluated by this technique and fungi can be detected in lesions at all corneal depths, including within deep stromal abscesses. *In vivo* corneal confocal microscopy is described as a method to detect, characterize, and localize microscopic corneal foreign bodies in horses. Corneal foreign bodies appear as moderately reflective or hyper-reflective linear, circular, or oval structures that do not resemble any normal corneal anatomic structures. The precise anatomic localization and depth measurements provided by *in vivo* corneal confocal microscopy can be used to assist in the selection of therapeutic or surgical plans for equine corneal foreign bodies. *In vivo* confocal microscopy is also described as a tool to assist with the diagnosis of corneal neoplasms in the horse, including lymphoma.

Optical coherence tomography

Optical coherence tomography (OCT) is a non-contact technique for obtaining high-resolution, cross-sectional tomographic images of the anterior and posterior segments of the eye. Optical coherence tomography utilizes the optical delay of reflected light and interferometry to measure distance and to produce images. Interferometry involves waves that are superimposed causing the physics phenomenon of "interference" to extract information.

Optical coherence tomography equipment utilizes a single source light beam that is split by a beam splitter into sample (tissue) and reference beams. These initially identical beams travel dissimilar optical paths creating phase difference between the beams. Sample and reference beam reflections are recombined and the interference pattern is detected by a photodetector, converted into a digital signal, and processed to produce a cross-sectional image. There are two primary OCT methods, time-domain OCT (TD-OCT) and spectral-domain OCT (SD-OCT, also known as Fourier-domain OCT and frequency-domain OCT). In general, spectral-domain OCT permits more rapid scanning speeds and greater image resolutions.

Descriptions of the anatomy of the cornea, retina, and optic nerve of clinically normal horses are published using portable or handheld SD- OCT devices. These studies examined standing, sedated horses and were able to obtain high quality images of the anterior and posterior segments. Corneal layers, including the epithelium, stroma, and endothelium-Descemet's membrane complex, were distinguished and measured. Retinal and optic nerve head images were obtained and manual measurements of the total retinal thickness, nerve fiber layer thickness, and the vertical and horizontal axis of the optic nerve head and optic cup were performed.

The OCT findings in horses with heterochromic iridocyclitis have been described. In this study of horses evaluated by SD-OCT, retrocorneal membranes and pigmented keratic precipitates appeared as highly reflective areas along the inner aspect of the endothelium-

Descemet's membrane complex that projected into the anterior chamber. The endothelium-Descemet's membrane complex was thickened with a highly reflective inner aspect that occasionally appeared detached (representing retrocorneal membrane detachment).

Specular microscopy

Specular microscopy is a noninvasive imaging technique that provides a rapid qualitative, quantitative, and morphometric evaluation of the corneal endothelium. Specular microscopes project light and capture the image that is reflected from the optical interface between the corneal endothelium and aqueous humor (a high magnification view of the specular reflected light from the corneal endothelium is produced). Both contact and noncontact specular microscopes are available. Many of these microscopes provide rapid and automated or semi-automated analysis of corneal endothelial cell density, endothelial cell morphology, and corneal pachymetry.

There is a single published study describing the use of noncontact specular microscopy in horses. In this study, enucleated globes from healthy horses were evaluated for endothelial cell density and corneal thickness.

Infrared thermography

Infrared thermography is a non-invasive, rapid, potentially remote method to measure ocular surface temperature. Radiated heat is emitted from the eye in the nonvisible infrared region of the electromagnetic spectrum. An infrared thermograph is a device, typically consisting of a specialized camera or video recorder system, which collects the radiation and then uses a photosensitive detector system to produce an image (termed a thermogram).

In horses, eye surface temperatures measured by thermography are associated with body temperature measurements and infrared ocular thermography is a potential screening tool for pyrexia. Infrared ocular thermography is also an objective method of detecting and assessing physiological stress in horses, particularly during athletic training or competition. Maximum eye temperature has been used as an effective measure of stress detection in horses during sport competitions, aversive management procedures, and with different housing conditions. Infrared thermography is used to assess ocular surface temperature changes in humans and other animal species with a variety of different ocular diseases. Characterization of equine ocular surface temperature changes with different ocular pathologies is limited; however, a recent study evaluated ocular infrared thermography in horses with acute uveitis.

Infrared photography

Infrared light is electromagnetic radiation with longer wavelengths than light in the visible spectrum and is normally not visible to the human eye. Infrared light is more efficiently transmitted through an opaque cornea and this principle can be used to visualize intraocular contents that would otherwise be obscured by corneal lesions. Infrared photography is accomplished by conversation of a standard digital camera or the use specific lens filters. Infrared photography is used to visualize the equine anterior chamber, iris, and lens under conditions where these structures would normally be at least partially concealed by corneal opacifications.

Selected references

Andrew SE, Ramsey DT, Hauptman JG, Brooks DE. Density of corneal endothelial cells and corneal thickness in eyes of euthanatized horses. *Am J Vet Res* 2001; 62: 479-482.

Ledbetter EC, Irby NL, Kim SG. *In vivo* confocal microscopy of equine fungal keratitis. *Vet Ophthalmol* 2011; 14: 1-9.

Ledbetter EC, Irby NL, Schaefer DM. *In vivo* confocal microscopy of corneal microscopic foreign bodies in horses. *Vet Ophthalmol* 2014; 17 Suppl 1: 69-75.

Ledbetter EC and Scarlett JM. *In vivo* confocal microscopy of the normal equine cornea and limbus. *Vet Ophthalmol* 2009; 12 Suppl 1: 57-64.

McMullen RJ Jr, Clode AB, Gilger BC. Infrared digital imaging of the equine anterior segment. *Veterinary Ophthalmology* 2009; 12: 125-131.

Negro S, Bartolome E, Molina A, Sole M, Gomez MD, Valera M. Stress level effects on sport performance during trotting races in Spanish Trotter Horses. *Res Vet Sci* 2018; 118: 86-90.

Pinto NI and Gilger BC. Spectral-domain optical coherence tomography evaluation of the cornea, retina, and optic nerve in normal horses. *Vet Ophthalmol* 2014; 17 Suppl 1: 140-148.

Pinto NI, McMullen RJ,Jr, Linder KE, Cullen JM, Gilger BC. Clinical, histopathological and immunohistochemical characterization of a novel equine ocular disorder: heterochromic iridocyclitis with secondary keratitis in adult horses. *Vet Ophthalmol* 2014; 18: 443-456.

Pirie CG, Alario AF, Barysauskas CM, Gradil C, Uricchio CK. Manual corneal thickness measurements of healthy equine eyes using a portable spectral-domain optical coherence tomography device. *Equine Vet J* 2014; 46: 631-634.

Rushton JO, Tichy A, Nell B. Introduction of the use of thermography and thermometry in the diagnosis of uveitis in horses: a pilot project. *Vet Rec Open* 2015; 2: e000089-2014-000089. eCollection 2015.

Vallone LV, Neaderland MH, Ledbetter EC, Dubielzig RR. Suspected malignant transformation of B lymphocytes in the equine cornea from immune-mediated keratitis. *Vet Ophthalmol* 2015; 19: 172-179.

FRIDAY SESSION
ABSTRACTS & CASE REPORTS

COMPARISON OF THE EFFECT OF INTRAVENOUS FLUNIXIN MEGLUMINE, PHENYLBUTAZONE AND ELECTROACUPUNCTURE ON OCULAR PAIN IN THE HORSE: A PILOT STUDY (Z Makra,[1] Sz Molnár,[1] N Csereklye,[1] K Veres-Nyéki,[2] MM Riera,[2] RJ McMullen,[3] Zs Abonyi-Tóth,[4] G Bodó[1]) Equine Department and Clinic, University of Veterinary Medicine Budapest, Hungary;[1] Royal Veterinary College, London, UK;[2] College of Veterinary Medicine, Auburn University, Alabama, USA;[3] Department of Biomathematics and Informatics, University of Veterinary Medicine Budapest, Hungary[4]

Purpose. To evaluate the effect of intravenous flunixin meglumine, phenylbutazone, and electroacupuncture on ocular pain in the horse using a multifactorial pain scale. **Methods.** Four horses underwent manual corneal epithelial debridement under clinical circumstances four times on alternating eyes keeping 1-month interval between the procedures (Permission No: 11/4/2015-MAB). In the 4 sessions, all horses got the following treatments postoperatively in a randomised order: flunixin IV, phenylbutazone IV (PBZ), electroacupunture (EA) or placebo. All horses were pain scored before corneal wounding, then every 2 hours until 10 hours post operatively, every 4 hours until 48 hours postop, and twice daily until the end of the 5th day – total of 18 time points. The ocular pain scale was consisted of 11 parameters. This pain scale was completed by three observers blinded to the analgesic treatment, pain scores were given by photos. Corneal wounds were defined as healed when fluorescein dye was no longer retained. For rescue analgesia morphine was given IM. Mean pain scores were used for statistical analysis. Differences in pain scores in treatment groups were analysed using one-sample t-test. Interobserver reliability was analysed using Bhapkar-test. **Results.** Degree of corneal pain significantly reduced by the 3rd postop day (p=0.0319) evaluating all 11 parameters. Five ocular symptoms (blepharospasm, lacrimation, eyelid swelling, corneal opacity, conjunctival hyperaemia/chemosis) showed significant difference in treatment time and proved to be good indicators of ocular pain. The other parameters (heart rate, corneal touch threshold, response to palpation, 3 behavioural parameters) were not relevant in evaluating the severity of pain. Evaluating 5 ocular symptoms, the lowest pain score was given in the flunixin group (1114), then EA group (1356), PBZ group (1397), and placebo group (1580). There were significantly lower pain scores (p=0.0197) in the flunixin group compared to the placebo group in the first 46 hours. Interobserver reliability of the pain score was low. **Conclusions.** From the evaluated treatments flunixin should be the best choice to treat corneal pain in horses. Reduction of the parameters in the scoring system and refinement of photo evaluation could be used in the future. Supported by 9877-3/2015/FEKUT grant. **None.**

HOW TO USE IV TUBING AS PROTECTIVE CONDUIT OVER SUBPALPEBRAL LAVAGE

(M Huck-Miller) Huck Equine Clinic, Jackson Missouri

Purpose. To describe a method using IV tubing as protective conduit to commercial subpalpebral lavage (SPL). **Methods.** IV tubing is trimmed of unnecessary drip chamber and adapter and then split longitudinally using scissors. SPL is placed in patient in traditional manner. Then, the plastic conduit is placed over the SPL and black tape is placed around the conduit every 10-20 centimeters apart. Excess conduit tubing is cut away. Bandage tape is secured over conduit and then sutured to patients face with #1 Braunamid and 18G hypodermic needle. The bandage tape piece used nearest the eye is placed such as the adherent portion is partially directly on the SPL and the rest over conduit tubing. **Results.** This method has been used in this author's practice for approximately 9 years. From 2014-2017, approximately 250 patients had SPL placement. Approximately 50% of these SPLs were new and 50% used. Four horses had SPL replaced during this time period due to damage. Although author suspects, the damage of ¾ of these SPLs was possibly from the SPLs being aged-multi-use and not necessarily patient damage; ¼ of the SPLs was damaged by patient and or mask. **Conclusions.** This is a simple, cost effective method allowing us to lessen the chances of damage to the SPL substantially therefore, decreasing the treatment cost to the owner of the patient, veterinarian time repairing tube, and irritation to the patient. Care needs to be taken in order to re-sterilize the SPLs if veterinarian chooses to re-use SPLs. **None.**

3D PRINTED EQUINE TRAINING EYE. DESIGN AND USE FOR TEACHING OPHTHALMOSCOPY, SLIT LAMP BIOMICROSCOPY AND OCULAR PHOTOGRAPHY.

(T Knott) The Equine Eye Clinic, Gloucestershire, UK

Purpose. To describe the design and production of a 3D printed Equine training eye model and it's use for training direct and indirect ophthalmoscopy, slit-lamp biomicroscopy and ocular photography. Particular reference is made to the localisation, examination and photography of opacities on the corneal surface, anterior and posterior lens and the examination and photography of the retina. **Methods.** The model consists of: i) A 3D printed cylindrical body which allows a printed retinal image to be slotted in to the bottom of the cylinder. A hole in the bottom of the cylinder allows light to enter behind the retinal picture to help demonstrate the principles of ophthalmoscopy. ii) A lens/pupil/anterior chamber simulacrum made from two 50mm glass cabochons placed planar side to planar side with a printed iris/pupil between the cabochons. Pupils of different shapes and sizes were printed to represent dyscoria, miosis, iridal cysts and mydriasis. Cabochons were painted to represent anterior corneal, anterior lens capsule, anterior subcapsular and posterior capsular opacities. This could be replaced with a 50mm spherical 20 dioptre lens for easier retinal examination. iii) a 3D printed retaining lid with a viewing hole. The models were used to demonstrate and train the identification and photography of lesions and normal. A similar, smaller, model was produced and used for simulating the canine, feline and laprine eye. **Results.** Translucent and opaque corneal and lens lesions were reproduced and localised by parallax using conventional and smart phone ophthalmoscopy and slit lamp microscopy. Conventional and smart phone macro photography was used successfully. Retinal examination was simulated using conventional and smart phone ophthalmoscopy. **Conclusions.** The training eye was inexpensive to produce, robust and easy to use allowing the demonstration and training of the identification and photography of a wide range of simulated normal and pathological ocular structures.

RISK FACTORS FOR ERU IN A POPULATION OF APPALOOSA HORSES IN WESTERN CANADA (LS Sandmeyer, [1] NB Kingsley, [2,3] CL Waldner, [4] S Archer,[5] ML Leis,[1] R Bellone,[2,3] BS Bauer [1]) [1]Small Animal Clinical Sciences, Western College of Veterinary Medicine, University of Saskatchewan; [2]Veterinary Genetics Laboratory, [3]Department of Population of Health and Reproduction, School of Veterinary Medicine, University of California, Davis; [4]Large Animal Clinical Sciences, Western College of Veterinary Medicine, University of Saskatchewan; [5]Moose Jaw Saskatchewan.

Purpose. To measure frequency of ERU on several breeding farms in Alberta (AB) and Saskatchewan (SK) and investigate risk factors for ERU in this population. **Methods.** A DACVO performed ocular examinations on all Appaloosas. Horses were diagnosed with ERU if there was presence of active uveitis in addition to historical evidence of previous episodes or continuous uveal inflammation. Pedigree analysis was completed on 18 affected horses. Risk factors for ERU and ERU severity were examined using logistic and ordinal logistic models with random intercepts for farm, exact logistic regression or non-parametric statistics as appropriate. **Results.** One hundred forty-five Appaloosas (99 female, 45 male) were examined on 11 farms. Ages ranged from 0.5 to 21 years. ERU was diagnosed in 20 (14%). Sex and base coat colour had no influence on risk of ERU. Risk of ERU and severity of disease increased with age. The few-spot appaloosa coat pattern had significantly more risk for ERU than a solid (no pattern) or white fleck (minimal) pattern. Horses with the *LP/LP* and *LP/lp* genotype were at significantly higher risk for ERU than *lp/lp*. Pedigree analysis identified a common ancestor among 14 of 18 affected horses. Eight of these are offspring of a single affected stallion, two of which were the product of inbreeding (COI=0.25 and 0.125). **Conclusions.** Genetics is a major contributor of risk for ERU. The *LP/LP* genotype carries the highest risk for presence and severity of ERU. Nine half-siblings of an affected sire support a major risk locus within this family. **Equine Health Research Fund, University of Saskatchewan. Morris Animal Foundation. None.**

ERU IN A POPULATION OF PONY OF THE AMERICAS IN THE USA (LS Sandmeyer, [1] NB Kingsley [2], C Waldner, [3] S Archer, [4,] BS Bauer [1], R Bellone, [2]) Small Animal Clinical Sciences, Western College of Veterinary Medicine, University of Saskatchewan; [1] [2]Veterinary Genetics Laboratory, [3]Department of Population of Health and Reproduction, School of Veterinary Medicine, University of California, Davis Veterinary Genetics Laboratory, University of California, Davis; [2] Large Animal Clinical Sciences, Western College of Veterinary Medicine, University of Saskatchewan; [3] Moose Jaw Saskatchewan.

Purpose. To describe ERU on a Pony of the America (POA) breeding farm and investigate risk factors for ERU in this population. **Methods.** Thirty-one POAs had ocular examinations performed by a DACVO. Horses were diagnosed with ERU if there was presence of active uveitis in addition to historical evidence of previous episodes or continuous uveal inflammation. Serology for Leptospirosis was completed in 13 horses. Pedigree analysis was performed on twelve affected horses. Risk factors for ERU and ERU severity were examined using exact logistic regression or non-parametric statistics as appropriate. **Results.** Thirty-one POAs (24 female, 7 male) were examined. Ages ranged from 4 to 21 years. ERU was diagnosed in 39% (12/31) of ponies. Risk of ERU significantly increased with age. Sex, base coat colour and pattern, *Leptospira* status, and *LP* genotype were not associated with the risk for ERU in this population. Although not significant, the *LP/LP* (OR: 3.5) and *LP/lp* (OR: 2.1) genotypes were more frequent in horses with ERU than the *lp/lp* genotype. All 12 affected ponies trace back to a single stallion within 3 generations, 8 of which were products of inbreeding to that ancestor. **Conclusions.** The clinical manifestations of ERU in the POA are similar to those of the Appaloosa horse. Statistical power was limited in this study; however, findings suggest a potential role of *LP* in the risk for disease and pedigree analysis supports the role of a major additive genetic risk factor in this breed. **Equine Health Research Fund, University of Saskatchewan. None. Morris Animal Foundation None.**

ACUTE AND CHRONIC RESPONSE TO SUPRACHOROIDAL TRIAMCINOLONE FOR TREATMENT OF POORLY-RESPONSIVE UVEITIS (B Gilger,[1] E Barr[1], C Hartley[2]) [1]Clinical Sciences, College of Veterinary Medicine, NC State University, Raleigh, NC USA; [2]University of Bristol Veterinary School, Langford, Bristol, UK.

Purpose. To evaluate clinical efficacy and complications associated with suprachoroidal injection of triamcinolone for non-responsive uveitis in horses. **Methods.** Horses with medically poorly-responsive acute, chronic, or recurrent uveitis were injected suprachoroidally with triamcinolone acetonide (TA) (200 uL; 4-5 mg) using a purpose-designed microneedle. **Results.** 12 horses were injected either once (n=10), twice (n=2) or 4 times (n=1) with 3 horses injected bilaterally (and 4 eyes receiving multiple injections). Fifteen eyes total were treated. Injections were performed in standing horses without difficulty and immediate or long-term complications were not observed following injections. Immediate reduction in signs of uveitis were noted as early as 1 week after injection. Cyclosporine implants were subsequently placed in 7 horses when uveitis appeared quiescent. Uveitis recurrence was observed 5 horses at mean 3.4 months (range 1-6 months) after injection. Three horses eventually had enucleation for recurrence of uveitis (1, 3 and 11 months after injection). One horse died of colic 2 months after injection. Repeat injections were performed approximately every 4 months (mean 4.3 months) in 4 eyes of 3 horses, of which 3 remain visual. Overall, at last examination, 9/15 (60%) eyes remained visual. **Conclusions.** Suprachoroidal TA injections are feasible, not associated with complications, and effectively suppresses intraocular inflammation in in most horses for 3-4 months, but repeat injections may be required to for long-term control of uveitis. However, long-term visual prognosis in these severe cases of uveitis remains poor.
Supported: NC State Univ. (P) Gilger.

Title: Image-Guided Intervention for Correction of Nasolacrimal Atresia

Author and Address:
Plummer CE; Berkowski WM; Ramos R; Brooks DE; Czerwinski S; Gallagher A.
University of Florida, Gainesville, FL 32610, USA

Topic Area: Adnexa

Case Summary:
Two cases in which a novel method of nasolacrimal duct neocanalization utilizing a ureteral catheter and balloon dilator with fluoroscopic and endoscopic guidance are described. Horses were diagnosed with nasolacrimal duct atresia based upon ophthalmic and nasal cavity examination, CT with contrast, and Jones I testing. Horses were considered for the novel procedure if atresia was too proximal to access by traditional means (n=1) or an attempt at traditional surgery was unsuccessful (n=1). Both patients underwent general anesthesia and were positioned in dorsal recumbency. The affected NLD was catheterized anterograde to the point of obstruction, and infused with contrast medium. Under fluoroscopic guidance, a trocar was introduced retrograde through the nasal aperture to create a new stoma through the mucosa into the NLD. An endoscopically guided balloon dilator was then used to enlarge the stoma, and a final in-dwelling catheter was placed retrograde through the stoma, extending along the full course of the NLD. The median duration of the procedure was 106 minutes. Moderate hemorrhage from the nasal mucosa was the only intraoperative complication, and it occurred in both horses. The in-dwelling NLD catheter was removed prematurely by one patient, resulting in loss of NLD patency and return of ocular discharge. The neocanalization procedure was repeated with success, resulting in resolution of ocular discharge. Both patients were comfortable and free of ocular discharge at the time of last follow-up, a minimum of 6 months post-operatively.

Key Words:
Nasolacrimal Duct Atresia, Image-Guided Intervention, Fluoroscopy, Conjunctivitis, Epiphora

Discussion Points:

- Different methods for correction of this congenital defect?
- Suggestions for post-operative monitoring and care?
- Is there any long-term data available on these cases?
- Inheritance pattern?

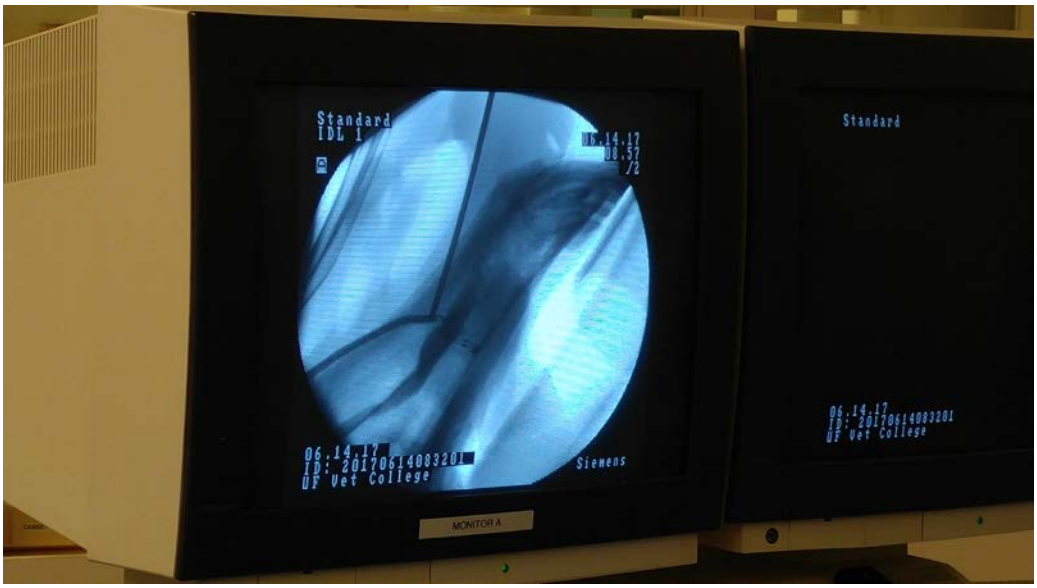

Figure 1: Fluoroscopy image of approach to contrast filled NLD.


Figure 2: Guide-wire in pace in canalized NLD.

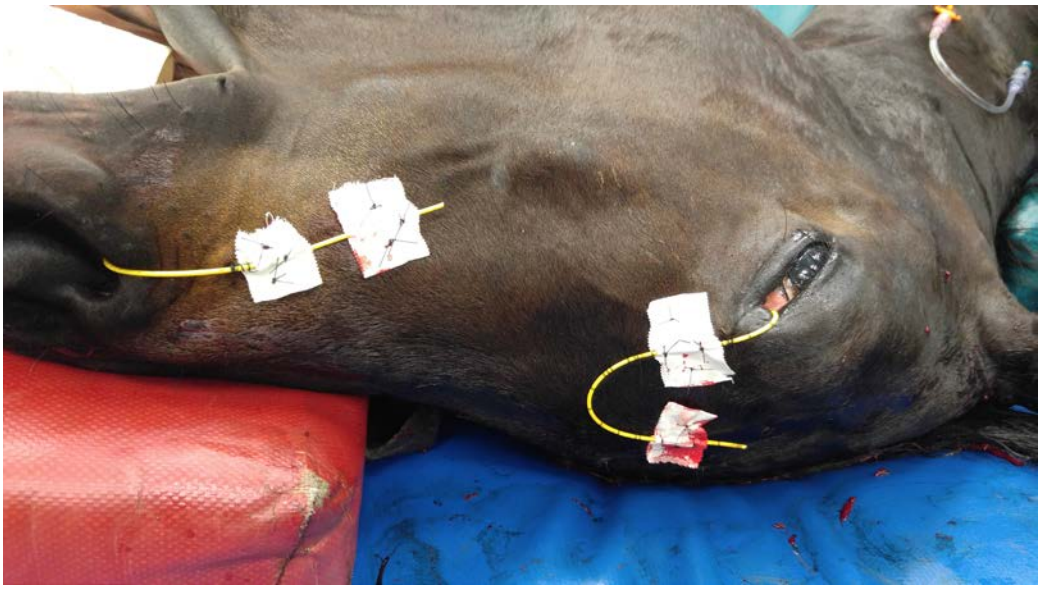
Figure 3: Post-operative appearance with stent in place.

Title: Radical Exenteration on Recurrent Equine Squamous Cell Carcinoma (SCC) of the Eyelid and Periorbital Region

Author and Address:
Pelych, L; La Croix, N
The Veterinary Medical Center of Long Island, West Islip, NY 11795
Hurcombe, S.
Cornell Ruffian Equine Specialists, Elmont, NY 11003

Topic Area: Squamous Cell carcinoma

Case Summary:
A 12-year-old Quarter Horse gelding presented with a large ulcerated proliferative mass of the left lower eyelid and adjacent skin. The left eye was nonvisual lacking a dazzle reflex and menace response. There was evidence of lysis and periosteal new bone development of the adjacent zygomatic bone. The soft tissue mass extended into the left caudal maxillary sinus. Endoscopy of the upper airway and guttural pouches did not show evidence of regional lymphadenomegaly. A radical exenteration of the horse's left globe, orbit, and periorbital structures was performed under general anesthesia. The mass had invaded both the frontoconchal and caudal maxillary sinuses. Post excision, these sinuses and the orbit were packed with QuikClot® Combat and Kerlix gauze. The facial skin was approximated with large tension relieving polydioxanone sutures, and the defect was packed with povidone-iodine soaked kling bandages. The site was covered with a tie-over bandage consisting of laparotomy sponges held by a tie-over stent bandage fixed with umbilical tape crisscrossed through polypropylene sutures. Histopathology revealed the excised mass as a squamous cell carcinoma with positive ("dirty") margins. Regrowth of the mass was not observed in the 6-month post-operative period. The horse subsequently died of an unrelated colonic volvulus.

Key Words:
Squamous Cell Carcinoma, Exenteration

Discussion Points:

- Treatments for ocular squamous cell carcinoma.
- Radical exenteration of orbital tumors
- Palliative but invasive procedures vs. euthanasia?

Figure 1: The left side of a 12-year-old Quarter Horse gelding's face at initial presentation prior to (left) and after (right) removal of a crusted exudate.

Figure 2: Left dorso 45° lateral-right ventrolateral oblique radiograph illustrating bone lysis (circled) and periosteal development (arrows) in the left zygomatic bone of a 12-year-old Quarter Horse gelding.

Figure 3: The left orbit of a 12-year-old Quarter Horse gelding 30-days after radical exenteration. The orbit remains open with healthy granulation tissue

Title: Piroxicam Treatment for Eyelid Squamous Cell Carcinoma in Two Horses

Author and Address:
Lynne Sandmeyer, Bianca Bauer, Marina Leis, Katherine Robinson
Western College of Veterinary Medicine, University of Saskatchewan, 52 Campus Drive, Saskatoon, SK, S7N5B4

Topic Area: Adnexa

Case Summary:
Two American Paint horses (ages 7 and 11) were evaluated for periocular skin lesions which appeared clinically similar to solar dermatitis, however skin biopsy and histopathology confirmed the lesions to be squamous cell carcinoma (SCC). Globe sparing therapeutic options were limited. Trial therapy was initiated in both cases with oral piroxicam at a dose of 110 mg/horse once daily. Re-evaluation of both horses after 6 months of piroxicam therapy revealed clinical resolution of the skin lesions. Repeated skin biopsies of the previously affected sites showed no evidence of SCC. Both horses continue to show no signs of recurrence at 2 and 4 years of ongoing therapy. No adverse side effects of treatment are noted. Piroxicam is a non-steroidal anti-inflammatory drug which suppresses cyclooxygenases-1 and -2 (COX-1 and 2) and has been used in treatment of some forms of cancer. Evidence in these horses suggests it may have success in the treatment of some forms of periocular SCC in horses.

Key words:
Squamous Cell Carcinoma, Adnexa, Piroxicam

Discussion Points:

- Options for treatment of adnexal SCC
- Role of inflammation in development of SCC
- Role of NSAIDS in therapy of different forms of cancer and in SCC

Figure 1. Appearance of periocular squamous cell carcinoma in a 11-year old Paint horse gelding to (left) and after (right) 2 years of oral Piroxicam therapy.

Figure 2. Appearance of periocular squamous cell carcinoma in a 7-year old Paint mare prior to (left) and after (right) 2 years of oral Piroxicam therapy.

Title: Orbitoscopy in a Horse with an Osseous Orbital Wound

Author and Address:
T. Launois[1], ECVS, DESV 1, DE.O, 1 Clinique du Lys – Bailly Vétérinaires – 663 avenue Jean Jaurès – 77190 Dammarie les Lys

Topic Area: Orbit, Arthroscopy, Wound.

Case Summary:
A 1 year old French Selle - Français mare presented with a deep upper orbital rim wound of the left eye exposing the zygomatic process of the frontal bone. Radiographic and ultrasound examinations were unremarkable. The mare was operated under general anesthesia. The wound was debrided and a thorough examination of the orbit was performed with an arthroscope to check for foreign bodies and allow copious lavage of the contaminated orbit. Cilia were retrieved with arthroscopic forceps. Erosions on the zygomatic process of the frontal bone were debrided with a curette. The periosteum was left open and the subcutaneous tissue and the skin were sutured. The wound healed in three weeks without any discharge. The left cornea developed slight corneal edema which resolved within one weeks, but did not show post-operative uveitis.

Points to discuss:

- Should we have done a Standing CT?
- Would you have used another surgical approach? Another surgical technique?

Figure 1

Figure 2

Figure 3

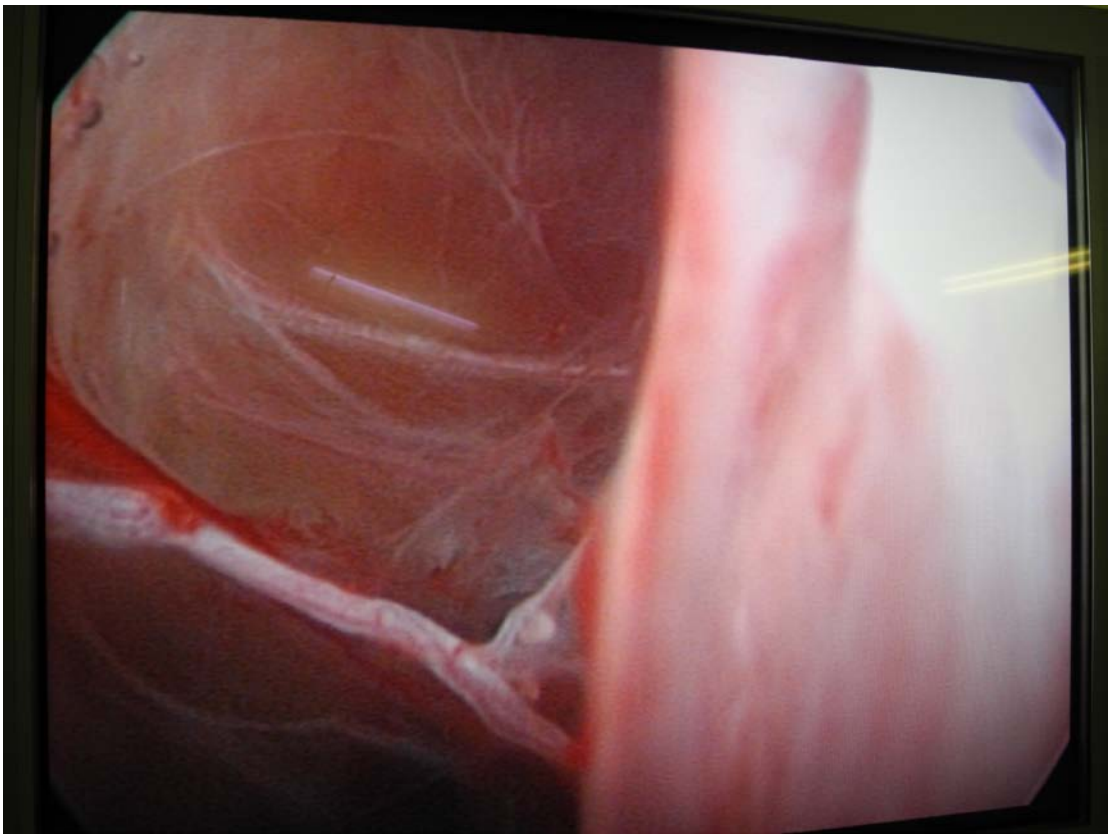
Figure 4

State of the Art Lecturer

Dr. Rebecca Bellone

Ph.D.
Director
University of California-Davis
School of Veterinary Medicine
Davis, CA

Dr. Rebecca Bellone earned her Ph.D. in Equine Genetics from the University of Kentucky in 2001. She has led an equine genetics research program involving both undergraduate and graduate students investigating the genetics of pigmentation and ocular disorders and the connection between the two. Her research team has collaboratively discovered causative mutations for both congenital stationary night blindness and ocular squamous cell carcinoma in horses. She was on faculty at the University of Tampa (FL) (2002-2014) where she was the recipient of several outstanding scholar awards. In 2014, she joined the faculty in the Department of Population Health and Reproduction at the School of Veterinary Medicine at the University of California, Davis and currently serves as the Director of the Veterinary Genetics Laboratory, a unit of the School, with an international reputation as experts in veterinary genetic testing.

Sponsored by:

an-vision

Dr. Rebecca Bellone, Ph.D.,
Director of Veterinary Genetics Laboratory,
University of California-Davis
One Shields Avenue
Davis, CA 95616

Seeing Equine Ocular Disorders thru a DNA Lens: Utilizing DNA Testing to Inform Clinical Management Decisions

Advances in equine genetics and collaborative transdisciplinary research has enabled a better understanding of the etiology of some inherited ocular disorder. Results from genetic testing can assist in clinical management and identify horses with or at risk for multiple congenital ocular anomalies, congenital stationary night blindness, ocular squamous cell carcinoma, and equine recurrent uveitis. In addition, genetic testing can inform breeding decisions to aid in lowering the incidence of disease. This presentation will review equine ocular genetic disorders for which DNA diagnostic tests exist.

I. Introduction, history, and review of equine genetics and genetic testing.

II. Congenital stationary night blindness (CSNB) in the Appaloosa and other LP breeds

- A. Leopard complex spotting and connection of pigmentation patterns to CSNB
- B. Genetic research to identify the causative mutation
- C. Breeds affected
- D. Utilization of the genetic test for CSNB-
  - *Important consideration *LP/LP* horses have CSNB but their coat color pattern is not always indicative of genotype

III. Equine recurrent uveitis (ERU)

- A. Leopard Complex spotting and ERU
- B. Research investigating ERU in the Appaloosa and related breeds
- C. Utilization of the genetic test for ERU
  - *Several lines of evidence support LP as an additive genetic risk factor with *LP/LP* horses at the highest risk of ERU. Therefore, genetic testing can be used as a screening tool to identify animals at greater risk.
- D. The genetics of ERU in non-LP breeds

IV. Multiple congenital ocular anomalies (MCOA)

- A. Connection of MCOA to the silver coat color dilution
- B. Mode of inheritance: incompletely dominant trait but perhaps also incomplete penetrance
- C. Breeds affected
- D. Utilization of the genetic test for MCOA
  - *Chestnut horses who have the silver mutation will not show the silver coat color but will be affected with MCOA. Homozygous *Z/Z* horses typically have a more severe phenotype.

V. Ocular squamous cell carcinoma (SCC) in the Haflinger and Belgian breeds

A. Genetic investigation of ocular SCC in the Haflinger breed identifies a recessive genetic risk factor in a DDB2 in Haflingers
B. Investigation of the genetics risk for ocular SCC in Belgian horses
C. Investigation of the DDB2 risk allele in other breeds and other SCC locations.
D. Utilization of the genetic test for ocular SCC

*This test will identify horses at the highest risk of developing ocular SCC and identify carriers. Other yet unknown genetic risk factors are also likely involved.

VI. DNA testing for disorders of other systems for which an ocular component has been identified.

VII. Conclusion- Genetic testing should complement ocular exams. DNA testing can identify horses that have the potential to produce offspring with ocular anomalies and identify horses who should be screened more frequently as they are at the highest risk for ocular disorders. In addition, DNA testing can be utilized to verify the biological mechanisms for a clinical diagnosis. With continued advances in our understanding of the equine genome, a better understanding of the biochemical pathways that lead to ocular disorders should be unraveled. Additional genetic testing should soon become available.

Seeing Equine Ocular Disorders thru a DNA Lens: Genetic Studies Underway

Several ocular disorders are believed to have a genetic basis. An increased understanding of the equine genome and the continued development of tools in which to study inherited disorders will enable a deeper understanding of the biochemical pathways that lead to these disorders. In some cases, unraveling functional mechanisms could lead to earlier detection and treatments that are more effective. Genetic studies are underway to identify additional genetic risk factors involved in ocular squamous cell carcinoma across breeds, equine recurrent uveitis in Appaloosas and related breeds, and bilateral corneal stroma loss and distichiasis in Friesian horses. This presentation will focus on the latest findings in these on-going studies.

I. Introduction to the horse genome and genomic research approaches and resources.

II. Identifying genetic risk variants for ocular SCC in Haflingers and Belgians

A. Introduction to ocular SCC
B. The recessive DDB2 risk allele explains approximately 80% of horses with ocular SCC in the Haflinger and Belgian breed and is likely the causal variant.
B. Pigmentation as another genetic risk factor
C. Genome wide association study identifies second risk locus in the Haflinger breed

III. Identifying of the genetic risk factors for equine recurrent uveitis (ERU) in the Appaloosa and related breeds

A. Introduction of ERU as a complex genetic trait
B. The role of LP in ERU risk and the likelihood that it is not the only genetic risk factor for ERU.

C. Genome wide association study identifies additional risk loci warranting further investigation in the Appaloosa
D. On-going work to recruit samples from Appaloosa, Knabstrupper, Pony of the Americas, and Warmblood breeds

IV. Genetic investigation of corneal dystrophy in Friesian horses
A. Introduction to research on corneal dystrophy in the Friesian breed
B. Pedigree analysis to identify mode of inheritance
C. Candidate gene investigation
D. Genome wide association study identifies risk loci warranting further investigation

V. Genetic investigation of distichiasis in Friesian horses
A. Introduction to research on distichiasis in Friesian horses.
B. Genome wide association study identifies risk loci warranting further investigation

VI. Conclusion: Strong collaborations between equine ophthalmologists and geneticists have allowed for the advancement of our understanding of inherited ocular disorders that has made DNA testing possible. Several studies to identify additional causative or associated variants for ocular disorders in the horse are currently underway. There are many other ocular conditions where a genetic contribution is suspected, for example cataracts in Morgan or American Quarter Horses. Continued collaborations that include expert phenotyping, collection and sharing of samples, and advancement in equine genomics research tools, will unveil the genetic components of additional and complex ocular disorders.

SATURDAY SESSION

ABSTRACTS & CASE REPORTS

ASSOCIATIONS AMONG ANTI-FUNGAL SUSCEPTIBILITY, MULTI-LOCUS SEQUENCE ANALYSIS, AND CLINICAL OUTCOME IN EQUINE FUNGAL KERATITIS (B Gilger[1], IQ Vander Schel[2], HVT Cotter[2], V Cornish[2], MA Cubeta[2], I Carbone[2], RJ McMullen[3], M Jacob[4]) [1]Clinical Sciences, College of Veterinary Medicine, NC State University, Raleigh NC; [2]Center for Integrated Fungal Research, College of Agriculture and Life Sciences, NC State University, Raleigh NC; [3]Auburn University Equine Ophthalmology, Auburn, AL; [4]Population Health and Pathobiology, College of Veterinary Medicine, NC State University, Raleigh NC USA

Purpose. To associate anti-fungal susceptibility and multi-locus sequence-based fungal identification with clinical outcome of equine fungal keratitis. **Methods.** Morphological characterization and DNA sequencing of fungal isolates obtained from clinical cases of fungal keratitis presented to the NC State and Auburn University Equine Ophthalmology Services were performed. The association of fungal species and lineage diversity with anti-fungal minimum inhibitory concentrations (MIC) to natamycin, fluconazole, voriconazole, metconazole, and moxifloxacin (negative control) and clinical outcome (response to medical therapy, surgical therapy or enucleation) was evaluated. **Results.** *Aspergillus* and *Fusarium* were the most common filamentous fungi isolated from infected horse eyes and identification was confirmed by morphological and DNA sequence characterization. Three species of *Aspergillus* (*A. flavus*, *A. oryzae,* and *A. fumigatus*) and three species of *Fusarium* (*F. falciforme*, *F. keratoplasticum,* and *F. proliferatum*) were identified. Fungal species and genetic lineage were not associated with clinical outcome. Voriconazole had higher MICs in *Fusarium* than *Aspergillus* isolates (4 and 0.5 median ppm, respectively) but were not significantly different (P=0.10). Isolates of *Aspergillus* had higher (P=0.003) natamycin MICs than *Fusarium* isolates with *A. flavus* exhibiting the least sensitivity. Isolates of both fungal genera had reduced MICs for metconazole (0.5-1.25 ppm), but higher MICs for fluconazole (≥156 ppm). **Conclusions.** Fungal species identification is critical for response to therapeutic agents and developing effective treatment recommendations. The results of this study suggest that anti-fungal treatment of equine keratitis should be tailored to the infecting fungi, and may require combination therapy for full efficacy.
Supported: NC State Univ. **None.**

EVALUATION OF VORICONAZOLE CONCENTRATIONS IN EQUINE TEARS FOLLOWING SUBCONJUNCTIVAL INJECTION OF CONCENTRATED ANTIFUNGAL COMBINED WITH THERMOSENSITIVE POLOXAMER GEL (RA Allbaugh,* L Sebbag,* TD Strong,* M Lerch,† JP Mochel, † DJ Borts†) Iowa State University College of Veterinary Medicine, *Department of Veterinary Clinical Sciences, †Department of Veterinary Diagnostic and Production Animal Medicine, Ames, IA 50011, USA

Purpose. To measure voriconazole drug levels in equine tears at numerous time points following administration of 2.5% voriconazole solution combined with a thermosensitive poloxamer gel (Thermaffix 20% gel, Med Specialties Compounding Pharmacy, Yorba Linda, CA). **Methods.** Six horses with normal, healthy eyes were used for the study. Five horses received a 0.3ml injection of 2.5% voriconazole/Thermafixx in the dorsal bulbar subconjunctival space of one randomly selected eye and 0.3 ml Thermafixx alone subconjunctivally in the contralateral eye. One horse was given 2.5% voriconazole/Thermafixx in both eyes to assess within-horse variability. Tear samples were collected from both eyes of each horse at baseline and numerous time points following subconjunctival injection (T= 10 and 30 min, 1, 3, 7, 12, 24, 36, 48, 60, and 72 hr) using polyvinyl acetal sponges. Tears were centrifuged from the sponges and stored at -80°C until analysis. Paper spray high-resolution accurate mass spectrometry (PS-MS) was used to quantitate voriconazole levels in tear samples following method validation. **Results.** PS-MS was able to measure voriconazole as low as 10 ng/mL. Voriconazole was present in tears of treated eyes for up to 3 hours following subconjunctival injection; however, large between-horses variability in drug concentration occurred as well as within-horse variability. **Conclusions.** PS-MS is a fast, reliable and sensitive method to analyze voriconazole in biofluids. Following subconjunctival injection of 2.5% voriconazole/Thermafixx controlled drug release was limited to only 3 hours and did not show the prolonged drug presence desired.
Partially supported by an Iowa State University College of Veterinary Medicine Seed Grant.
None

EQUINE SUPERFICIAL NON-HEALING CORNEAL ULCERS: A RETROSPECTIVE EVALUATION OF 58 CASES (2001-2017) (VJS Prucha[1], A Tichy[2], and B Nell[1]) Department of Companion Animals and Horses, University of Veterinary Medicine Vienna;[1] Department of Biomedical Sciences, University of Veterinary Medicine Vienna.[2]

Purpose. Evaluation of treatment protocols, clinical courses and outcomes of superficial non-healing corneal ulcers (SNHCU). **Methods.** Retrospective review of medical records of 58 horses diagnosed with SNHCU at the VMU Vienna (Dec 2001-2017). Data included affected eye, signalment, clinical symptoms, season of diagnosis, treatment protocols complications, and, corneal healing rate. **Results.** Sixty four eyes showed signs of a SNHCU. Follow-up information was available for 47/64 eyes. For those treated medically mean corneal healing rate was 15.55 days (±SD 12.23). Medical treatment included topical antibiotics, antimycotics, cycloplegics, and systemic anti-inflammatory drugs. Ten eyes received treatment with a poly-carboxymethylglucosesulfate regenerating agent (Cacicol®, Thea Pharma GmbH, AUSTRIA). Other common additional treatments included debridement with an iodine drenched cotton tip (75.0%, n=45) and diamond burr debridement (46.7%, n=28). Cauterization or debridement with a dry cotton tip or a surgical blade was rarely performed. A bandage contact lens (BCL) was used for 10 eyes. Each eye received at least one of those additional treatments, albeit none of them led to a statistically significant alteration in healing time over medical treatment alone. Only usage of a BCL showed a significant increase in healing time (p=0.027). When all treatments failed, most commonly superficial keratectomy with placement of a conjunctival flap (21.2%, n=14) was performed. Secondary complications included keratitis, keratomycosis, keratomalacia, and corneal-abscess formation. **Conclusions.** Results correlated with those previously described and thus demonstrated the difficulty and complexity of this disease. Further research is needed to determine optimal treatment protocol for superficial non-healing ulcers in horses. **None.**

THE EFFECT OF BODY POSITION ON INTRAOCULAR PRESSURE IN ANESTHETIZED HORSES (JM Meekins, [1] RM McMurphy, [1] JK Roush [1]) Department of Clinical Sciences, College of Veterinary Medicine, Kansas State University. [1]

Purpose. To evaluate the effect of four recumbent body positions on intraocular pressure (IOP) in anesthetized normal horses. **Methods.** IOP was measured with a rebound tonometer in both eyes (n=20) of standing sedated horses (baseline), then in four different anesthetized recumbent positions, including Trendelenburg (15-degree head down), reverse Trendelenburg (15-degree head up), dorsal, and lateral. Each horse was placed in both right and left lateral recumbency, however only the superior eye (n=10) was measured in the lateral positions. The mean of 3 IOP readings was taken at each position, allowing a minimum of 2 minutes to elapse after every change in position before obtaining IOP measurements. The order of body position change was randomized for each horse. Repeated Measures Analysis with Newman-Keuls Multiple Comparison Posthoc was used to compare IOPs in different body positions, and linear regression was used to compare IOP with age and weight cofactors. **Results.** When compared to baseline, the greatest change in IOP occurred in Trendelenburg (increase of 25.63±8.12 mmHg). When comparing all recumbent positions to baseline, IOP significantly increased in 3 of 4 body positions, with no significant difference identified between reverse Trendelenburg and baseline. When comparing all body positions to each other, the greatest IOP difference occurred between the Trendelenburg and the reverse Trendelenburg positions (increase of 26.95±5.41 mmHg). Age and weight were not correlated with IOP in any position. **Conclusions.** Body position significantly increases IOP in normal eyes of anesthetized horses. Supported by a KSU Mentoring Fellowship Award. **None.**

Title: Corneal Hemangiosarcoma in a 27 Year Old Arabian Gelding. Treatment and One Year Follow Up

Author and Address:
Voyles, M.
Veterinary Ophthalmology Services
Nashville, TN 37204

Topic Area: Cornea

Case Summary:
A 27 year old Arabian gelding presented for evaluation of a hemorrhagic mass OD. The mass had reportedly been present for 4 years and was size of pencil eraser initially. The mass had enlarged significantly two months prior to examination with no response to topical 5-Fluorouracil. Ophthalmic examination demonstrated a large, lobulated hemorrhagic mass at the temporal limbus OD extending into the paraxial cornea. OD was visual and the remainder of the ophthalmic examination was otherwise unremarkable. A superficial keratectomy followed by cryotherapy with liquid nitrogen and placement of conjunctival graft was performed without complication. Histopathology was consistent with corneal hemangiosarcoma accompanied by lymphoplasmacytic keratitis and solar elastosis. Neoplastic cells extended to the deep surgical margins. The horse was lost to follow up until one year post surgery. Examination of OD at this time revealed a comfortable, visual eye that demonstrated focal areas of prominent vasculature and a small raised vascular “mass” in the central area of the conjunctival graft. These changes had reportedly been present for at least 6 months. No peripheral lymphadenopathy or signs of metastasis were present, and no additional diagnostics were performed.

Key Words:
Hemangiosarcoma, Keratectomy, Cryotherapy, Solar Elastosis

Discussion Points:

- Is keratectomy a reasonable option for suspected corneal hemangiosarcoma?
- Why is this hemangiosarcoma more “benign” in behavior compared to other angiosarcomas in horses?
- Does solar elastosis contribute to hemangiosarcoma formation in horses?
- Is the mass reoccurring? Additional treatment recommendations? (if owners would agree)


Figure 1


Figure 2

Title: Resolution of Recurrent DSA with Surgical Excision in Two Horses

Author and Address:
Plummer CE; Berkowski WM; Ramos R; Proietto LR; Brooks DE.
University of Florida, Gainesville, FL 32610, USA

Topic area: Cornea

Case Summary:
Two cases re-presented with recurrent lesions following excision of a solitary deep corneal stromal abscess followed by corneal reconstruction via deep lamellar endothelial keratoplasty (DLEK). Both cases initially exhibited improvement in clinical signs (blepharospasm, anterior uveitis) following the surgical procedure, but within 3-4 weeks of surgery began to shown signs of discomfort and worsening uveitis. Deep stromal/endothelial lesions were appreciated immediately adjacent to the surgical site in both cases. Increased medical therapy was ineffective at controlling uveitis or resolution of the corneal lesion. A second, more extensive surgical approach was made to remove “satellite” lesions and the original corneal transplant graft in both cases. Resolution was complete and both eyes retained vision

Key Words: Corneal Stromal Abscess, Satellite Abscess, Uveitis

Discussion Points:

- What is different about these recurrent forms?
- Role of iatrogenic trauma and spread?
- Have others had success with satellite abscesses?

Figure 1: Satellite abscess that formed following DLEK

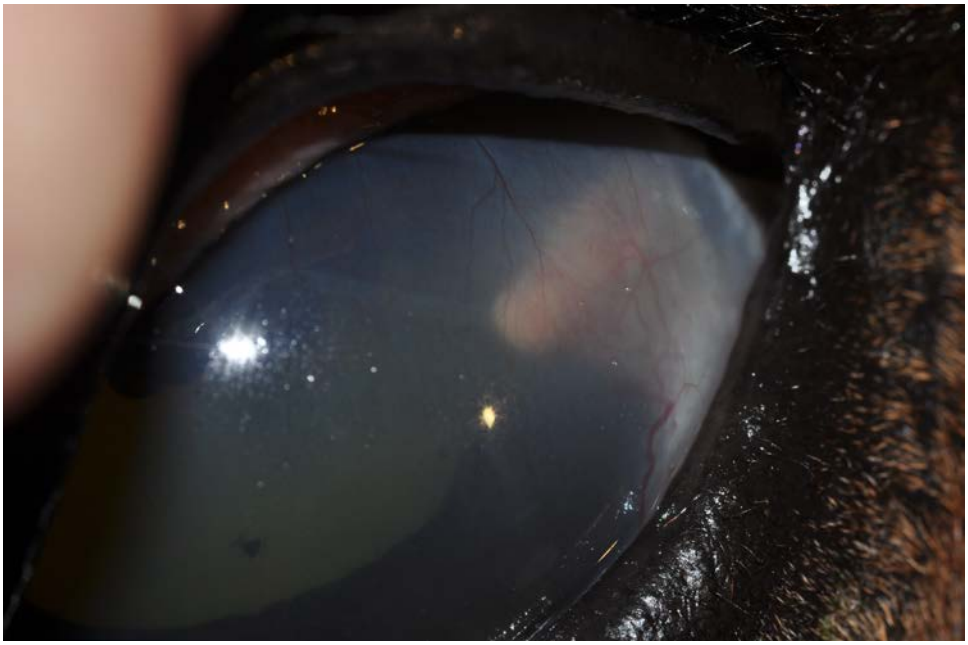

Figure 2: Satellite abscess progressing one week later

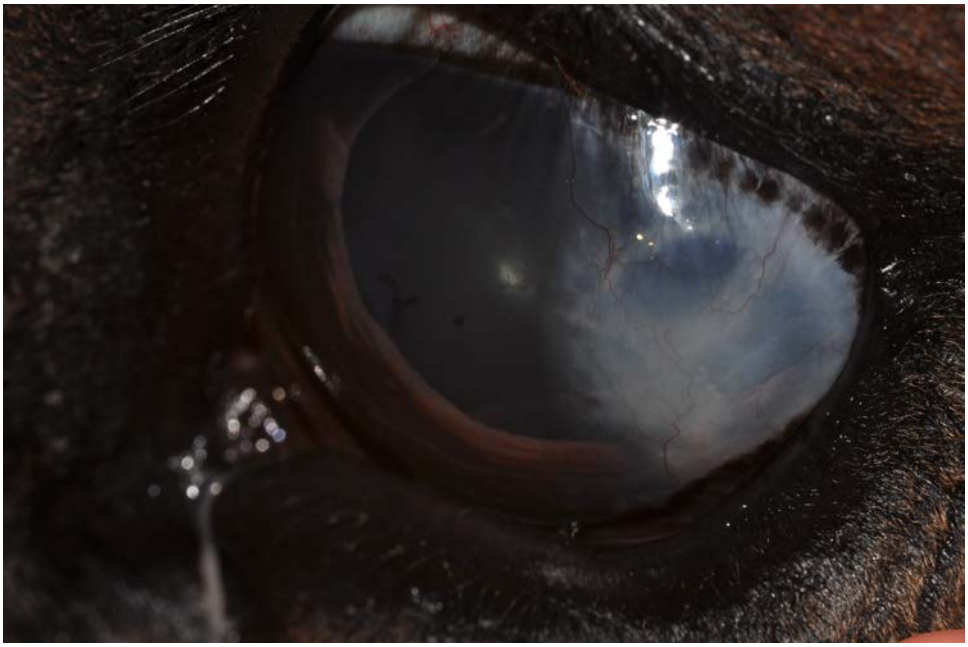

Figure 3: Post-operative appearance one month following second keratoplasty

Title: Lamellar Defect in the Posterior Cornea of a 2 Year Old Thoroughbred Filly

Author and Address:
McGovern, K.F[1]; Ricardi, G[1]; Patterson, B[2]
Donnington Grove Veterinary Group, Oxford Road, Newbury, Berks, UK, RG142JB[1], Animal Eye Consultants Ltd, 27 Coombe Road, Wotton Under Edge, Glos, GL12 7LZ[2].

Topic Area: Cornea

Case Summary:
A 2 year-old Thoroughbred filly presented for periocular swelling of the right eye, after being found cast. The filly was non-visual in the affected eye. Diffuse, marked corneal oedema was present, with corneal hemorrhage in the nasal quadrant. There was no evidence of globe penetration. Fluorescein staining was negative. Empirical treatment with systemic and topical anti-inflammatories was instigated. On day 3 post-presentation, findings were unchanged except for superficial ulceration in the central cornea. Ocular ultrasound revealed a marked increase in corneal thickness, consistent with oedema and anterior chamber echogenicities consistent with fibrin / hemorrhage. Systemic anti-inflammatories and antimicrobials were given, as well as topical antimicrobials and atropine. Repeat ocular ultrasound on day 9 revealed a substantial lamellar defect in the posterior cornea, affecting approximately 80% depth and 25% corneal width, but sparing the anterior lamellae. Blunt trauma was the suspected cause of the deep lamellar injury. The corneal ulcer healed routinely and on day 17 the filly appeared visual. Ultrasound examination on day 30 revealed significant improvement in the corneal lamellar defect size. Ophthalmic ultrasound examination on day 61 revealed resolution of the deep lamellar defect. Corneal oedema resolved with fibrosis remaining at nasal corneal quadrant. The filly was visual.

Key Words: Ultrasound, Trauma, Posterior Lamellar Defect

Discussion Points:

- Repeat ocular ultrasound is indicated in the management of suspected globe trauma involving corneal symptoms.
- Why was the corneal defect not noted initially?
- Blunt trauma could result in damage to the posterior cornea without involving the anterior cornea
- Substantial damage to the posterior corneal lamellae has the potential to remodel with vision being retained

Figure 1: Presentation on day 3.

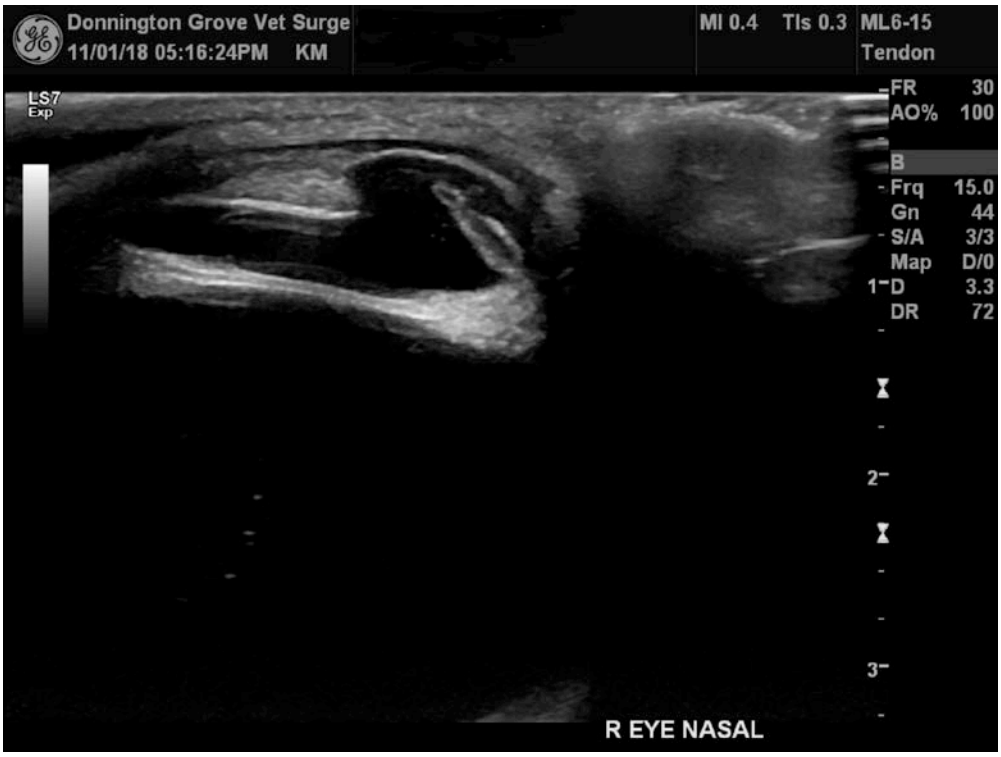

Figure 2: Ultrasound from day 9. Posterior corneal lamellae defect visible.

Title: Immune Mediated Keratitis in a Thoroughbred Gelding

Author and Address:
Dwyer, AE
Genesee Valley Equine Clinic, Scottsville, NY 14546

Topic Area:
Cornea

Case Summary:
A 10 year old TB gelding presented in 2003 for evaluation of a vascularized stromal opacity of the inferior nasal quadrant of the right cornea. Topical treatment for immune mediated keratitis (IMMK) was instituted. After the original diagnosis the horse experienced multiple "flares" of IMMK that were treated with a variety of topical medications. The geographic pattern of stromal infiltrate and vascularization varied widely during flares. Flares were followed by quiescent periods where some opaque corneal sectors or foci became transparent again. Topical treatment varied, but was minimal during recent years. Flares were observed on more than one instance within a few days of routine immunization, so all vaccine administration was eventually discontinued. A minority of relapses were accompanied by ulcerative keratitis and severe discomfort requiring SPL therapy. The horse remains visual nearly fifteen years after initial presentation. There is mild diffuse opacity of the inferior nasal and axial sectors of the cornea; additional focal areas of infiltrate are visible on slit lamp examination. Photographs demonstrating the severity of multiple episodes, and the return to transparency in quiescent periods, illustrate how IMMK can wax and wane.

Key Words: Cornea, Immune Mediated Keratitis, Immunomodulation

Discussion Points:

- Treatment of immune mediated keratitis?
- What are triggering events for the initiation or for flares of IMMK?
- Why does the affected corneal sector and geographic pattern vary over time in some horses?
- Why is vascularization an inconsistent feature of IMMK?

Title: Bilateral Corneal Stromal Loss in a 24-year-old Haflinger Mare

Author and Address:
Hermans, H., Slenter, I.J.M., Boevé, M.H.
Utrecht University, Faculty of Veterinary Medicine, Department of Equine Sciences, Surgery, Yalelaan 112, 3584 CM, Utrecht, The Netherlands

Topic Area:
Cornea

Case Summary:
A 24-year-old Haflinger mare was presented to the Department of Equine Sciences of the Utrecht University with bilateral recurring corneal edema/ulcerations since 2,5 years. The ulcerations had previously responded to topical ointments (antibiotics / vitamins) but recurred soon after cessation of treatment. Since two days the horse had severe ocular pain of the left eye.
Upon ophthalmic examination the right eye showed a fluorescein negative corneal facet inferotemporally of 3-4mm, without other ocular abnormalities.
There was severe blepharospasm and mucopurulent discharge of the left eye. A corneal perforation showing a 4mm iris prolapse was noted inferotemporally. The anterior chamber was shallow with hyphaema and fibrin and the pupil was miotic.
Due to the history of bilateral recurring corneal ulcers and the bilateral corneal abnormalities on ophthalmic examination the presumptive diagnosis of Bilateral Corneal Stromal Loss (BCLS) was made as described in the Friesian horse.
Surgical intervention was opted but due to financial constraints the left eye was enucleated and the right eye was left untreated. Histopathology of the left eye was performed.

Key Words:
Cornea, Dystrophy, Ulceration, Bilateral Corneal Stromal Loss, BCSL

Discussion Points:

- Is the presumptive diagnosis correct?
- Do we need to worry about BCSL in the Haflinger?
- What is the risk of perforation of the right eye?
- What are the treatment options of the right eye?


Figure 1. Corneal edema inferotemporally of the right eye (2015)


Figure 2. Corneal edema inferotemporally of the left eye (2016)


Figure 3. A corneal perforation showing a 4mm iris prolapse inferotemporally of the left eye (2018)

Title: Spontaneous Healing of a Traumatic Lens Capsule Rupture in a Horse

Author and Address:
Dietrich U, Dunkel B.
Queen Mother Hospital for Animals/Equine Medicine/Ophthalmology
Royal Veterinary College
Hawkshead Campus, Hawkshead Lane
North Mymms, Herts, Hertfordshire AL9 7TA
United Kingdom

Topic Area: Lens

Case Summary:
A 2 year-old Thoroughbred Mare was presented with the history of a suspected ocular injury to the left eye, which happened the day before, possibly caused by a nail. A small pinpoint full-thickness corneal injury was noticed in the ventro-lateral quadrant of the cornea, which had sealed and was fluorescein negative. There was a dense fibrinous sheet and fibrin clump attached to the lens and endothelium, and moderate flare noticed in the anterior chamber. A large anterior capsular tear extending from the ventral to dorsal aspect of the lens with mild protrusion of lens material into the most lateral anterior chamber was detected upon pharmacologic dilation of the pupil. Surgical treatment (lens removal surgery) was recommended to the owner which instead opted for medical treatment despite the guarded prognosis for the eye. Treatment consisted in intracameral injection of tissue plasminogen activator to dissolve the fibrin, as well as topical and oral antibiotics, atropine and topical and oral anti-inflammatory drugs applied via SPL. The horse was rechecked about 1 month following the initial injury. At re-examination, the eye was visual and comfortable, normotensive with no active inflammation noticed in the left eye. The previous capsular tear had completely sealed and the protruding lens material had dissolved. A large posterior synechiae covered the previous lens injury. The remaining part of the lens was clear and fundic examination was normal.

Key words:
Traumatic Lens Capsule Rupture, Complications, Fibrous Metaplasia of the Lens Epithelium, Phacoclastic Uveitis, Traumatic Cataract

Discussion Points:

- Medical versus surgical treatment of traumatic lens injuries in horses
- Healing capacity of lens injuries in horses and other animals (fibrous metaplasia)
- Complications of lens injuries
- Long-term prognosis?

Figure 1. The left eye at presentation. There is a dense fibrinous sheet covering the anterior lens capsule and fibrin clot attached to the endothelium of the penetrating injury



Figure 2. The left eye after tPA injection. The capsular tear is visible with lens material protruding at the lateral aspect.

Figure 3. Examination of the eye one week post injury. The capsular tear is clearly visible with lens material mildly protruding at the lateral aspect and focal cataract formation in the lens.

Figure 4. Left eye 1 month post injury. The lens capsule has completely flattened and the area of previous lens laceration and lens material protrusion has sealed with fibrosis. The eye is comfortable, visual and normotensive.

Title: Trabecular Meshwork Fibrosis Associated with Primary Glaucoma in an Adult Lipizzaner Gelding

Author and Address:
Scott, EM[1]; Teixeira, LBC[2]
Texas A&M University, College Station, TX 77843[1]
University of Wisconsin-Madison, Madison, WI 53706[2]

Topic Area: Glaucoma

Case Summary:
A 27-year-old Lipizzaner gelding was presented to the TAMU Ophthalmology Service with a 1-month history of intermittent blepharospasm and corneal edema OS. Ophthalmic examination revealed a blind eye with diffuse corneal edema, linear keratopathy, narrow and fibrotic iridocorneal angle (ICA), and an intraocular pressure (IOP) of 41 mmHg. The normotensive fellow eye exhibited a similarly narrow and partially obstructed ICA. There was no clinical evidence of active or chronic uveitis OU. Primary glaucoma was suspected and medical therapy was initiated with 2% dorzolamide/0.5% timolol ophthalmic solution 3 times daily OS. The patient re-presented 2 days later acutely painful with an IOP of 69 mmHg OS. Enucleation was elected and performed. Histopathologically, the sampled ICAs were distorted with narrowing of the ciliary cleft and marked collapse of the trabecular meshwork (TM). There was extensive melanin pigment dispersion throughout the TM, along with the presence of marked amounts of homogenous acellular eosinophilic extracellular matrix (ECM) material. Masson's trichrome stain confirmed the presence of collagen within the TM ECM. Congo red for amyloid failed to stain the TM. This case presents a form of idiopathic glaucoma where the likely mechanism of elevated IOP is due to TM fibrosis and pigment dispersion.

Key Words:
Equine Glaucoma, Ocular Pathology

Discussion Points:

- Primary glaucoma is an infrequently diagnosed disease in the horse.
- Iridocorneal angle lesions in horses with primary glaucoma are not well defined or clearly demonstrated.
- The deposition of collagen-rich extracellular matrix material in the trabecular meshwork may be an underlying mechanism for primary glaucoma in horses.

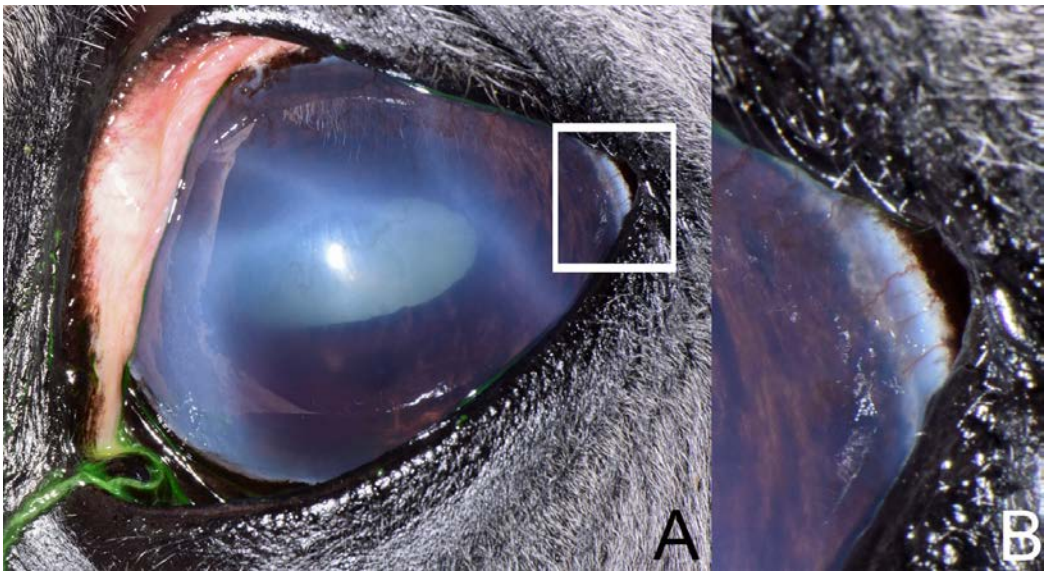

Figure 1. Initial presentation of the glaucomatous eye (A) with magnification of the narrow and fibrotic iridocorneal angle (B).

Figure 2. Photomicrograph of the iridocorneal angle. There is pigment dispersion and deposition of eosinophilic extracellular matrix material throughout the collapsed trabecular meshwork (arrowheads). H&E, Scale Bar = 200um.

Title: Primary Glaucoma in a Horse

Author and Address:
Townsend, Wendy; Stein, Leah; Sledge, Dodd
Purdue University, 625 Harrison St., W. Lafayette, IN 47907-2026
Michigan State University Veterinary Diagnostic Laboratory, 4125 Beaumont Rd., Lansing, MI 48910-8104

Topic Area: Glaucoma

Case Summary:
A 16-year-old Tennessee Walking horse gelding presented for intractable uveitis and corneal ulceration OD. On presentation, OD was blind, slightly buphthalmic, and had mild diffuse corneal edema, a central superficial corneal ulcer, corneal vascularization, corneal pigmentation, mydriasis, and an IOP of 51mmHg. No flare was noted. The iridocorneal angle OD was markedly recessed and could not be visualized. The view of the lens and retina were hazy, but there was mild optic nerve cupping. OS was visual and had an IOP of 20mmHg, normal cornea, no flare, positive direct PLR, areas of iridocorneal angle narrowing, a fine fibrous membrane along the dorsal pupillary margin, incipient cataract, and normal retina. OD was enucleated. Histologically, there was severe collapse of the ciliary cleft and extensive descemetization of pectinate ligaments. There was minimal lymphoplasmacytic anterior uveitis, but none of the classic features of chronic ERU, such as amyloid deposits. Additionally, he had temporal peripheral cobblestone retinal degeneration and a focal nasal peripheral retinal defect that corresponded to a grossly observed retinal tear, and was characterized by complete loss of the retina and RPE, and choroidal fibrosis.
Within one month, the owner reported vision loss OS. He is being managed by the rDVM.

Key Words: Glaucoma, Primary Glaucoma, Pectinate Ligament

Discussion Points:

- Is this primary glaucoma in a horse?
- What's the significance, if any, of Descemet's membrane segmentally covering the pectinate ligament?
- Should he have received prophylactic therapy in the fellow eye?
- What is the significance of the retinal changes including the tear and cobblestone retinal degeneration?

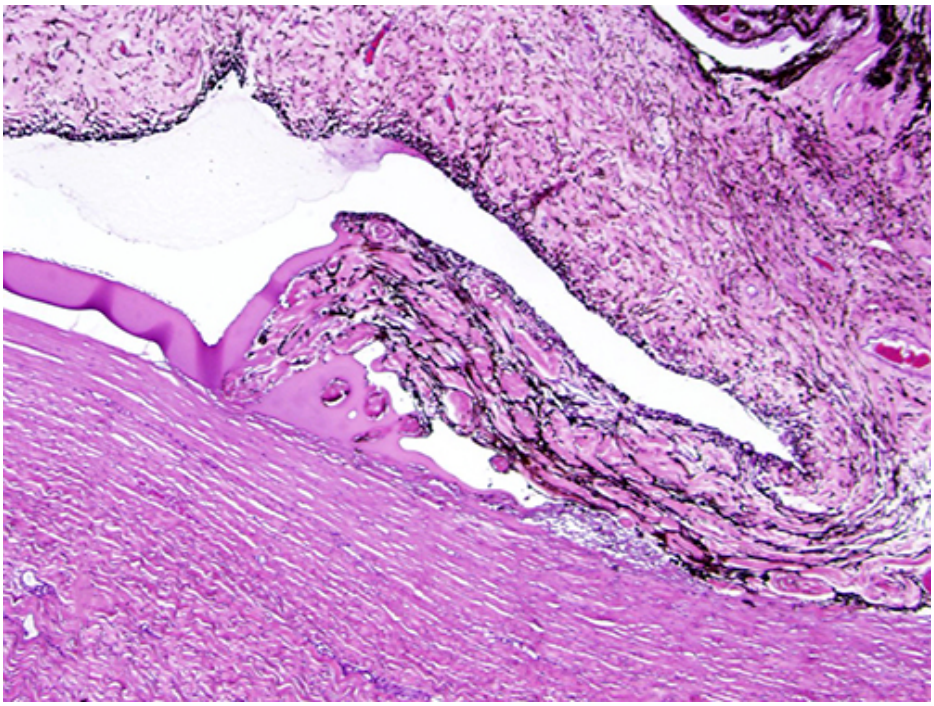

Figure 1: The descemetization of the pectinate ligaments and collapse of the ciliary cleft.

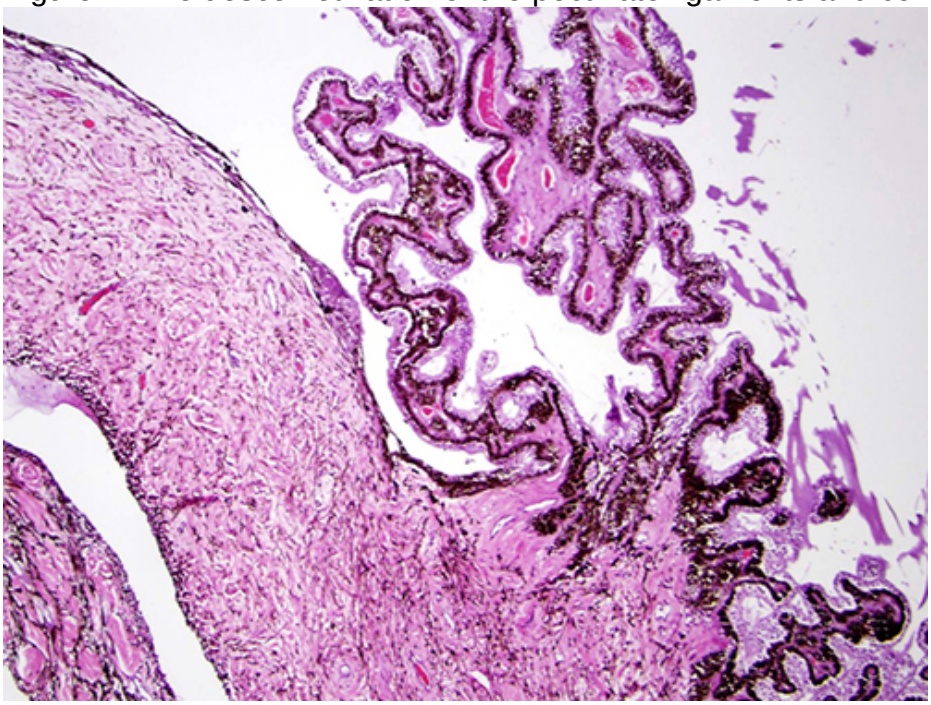

Figure 2: The ciliary body showing the lack of inflammation and lack of amyloid deposits.

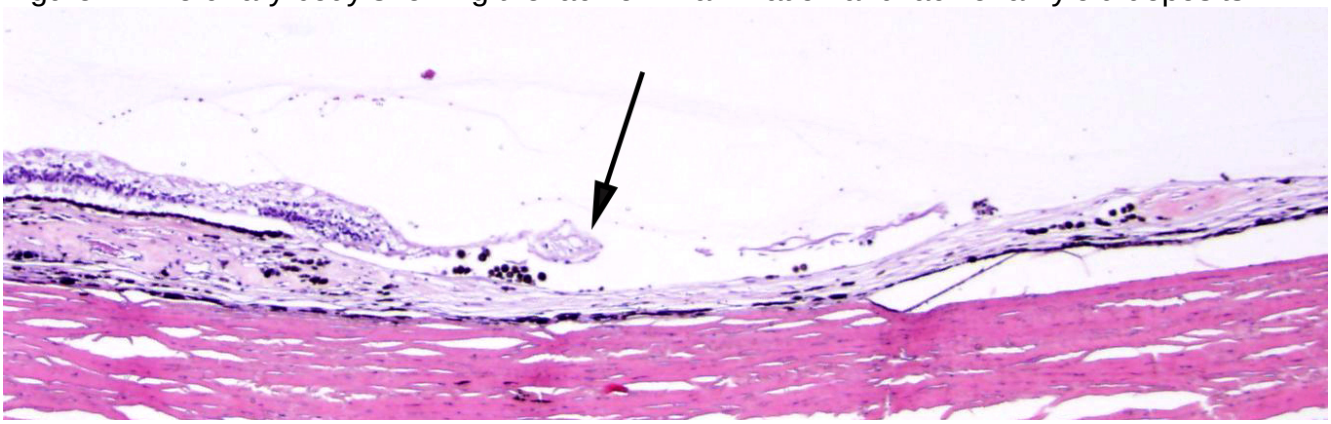

Figure 3: The peripheral retinal tear can be seen at the tip of the arrow.

Title: Post-Anaesthetic Central Blindness in a Stallion

Author and Address:
Makra, Z; Bodó, G
Equine Department and Clinic, University of Veterinary Medicine Budapest, Hungary

Topic Area:
Neuro-Ophthalmology

Case Summary:
This case report describes a post-anaesthetic central blindness caused by suspected air embolism associated with IV catheter disconnection in a horse. A 5-year-old Holstein stallion was anesthetized for castration and sarcoid removal. The anaesthetic period was unremarkable. During anaesthetic recovery the injection cap on the jugular venous catheter became dislodged. After 15 mins of standing he became recumbent again and had tachycardia, dyspnoea, seizures, sweating and nystagmus in the recovery box. Immediate nasal oxygen insufflation, flunixin meglumine, dexamethasone and glucose infusion were given. One hour later he stud up again, however showed blindness, so underwent complete ophthalmic examination. He had bilateral mydriasis, dPLRs and dazzle were intact but absent menace responses and maze tests confirmed bilateral blindness. Exam findings of the anterior and posterior segments OU were normal. Mannitol infusion, dexamethasone, flunixin, vitamin C, E and tiamin were administered for 5 days postop. By the 4th day pupil sizes became normal, vision gradually improved, although resolution of blindness was asynchronous between eyes. He was discharged from the clinic after 7 days, full regain of vision was reached after 2 weeks. Signs of transient central blindness were considered most likely to have resulted from a venous air embolism and subsequent cerebral ischemia.

Key words:
Central Blindness, Air Embolism, Post-Anaesthetic Complication, Positive Outcome

Discussion Points:

- How do you prevent IV catheter disconnection?
- What kind of diagnostic confirmation of air embolism could be performed?
- How would you treat cerebral hypoxia?